Sr No.	Topic.	Page No.
1.	AV Pattern	1.
2.	SO Palsy.	4.
3.	Examination of Case of Squint:	7.
4.	~~EOM & their physiology~~. Classification of Squints.	8
4.	Angle Kappa	11
5.	Cover test / Uncover test	12.
6.	Corneal Reflex test / Diplopia Assessment	14
7.	Limitation of Move^{n}	16.
8.	Suppression	17.
9.	HHDT	19.
10.	Synaptophore.	20.
11	EOM	22
12.	Sherington. law of Reciprocal Inhibition	24
13.	Weakening procedures on IO	26
14.	Classification of EOM	30
15.	Adaptation to Squint.	31
16	ARC	33
17	Hyperacuity.	34
18	Stereo-acuity test.	33
19	Esotropia.	38.
20	~~Accomodo~~ Mucotropia	42
21	Exotropia.	45
22.	Paralytic Squint	51
23.	DEP.	56
24	INO.	60
25	CPEO.	62
26	Restrictive Strabismus.	64
27	Brown Syndrome.	67
28	CF EOM	69
29	Vertical Strabismus.	70
30	DVD	72.

PAGE

DATE

Nystagmus	74
Non Surgical Mx of Squint	83
Botulinum Toxin A	85
Conj Incision in Squint Sx	88
Weakening procedures in Recti Mol	90
Steengthening procedures on Recti	94
Surgery on Oblique Mol	98
Complication of Strabismus Sx	101
Synaptophore	105
Cheiroscope	107
Atom 1, 2	
Amblyopia.	
AC: A Ratio	28
Stereopsis	

A-V Patterns

Urset's Lavalia.

Vertically Incomitant Comitant Horizontal Deviations

Pattern Type

- A
  - Exo
  - Eso
- V
  - Exo
  - Eso
- X
- Y (Brown)
- ◇ Diamond
- ⅄ (Delta)

May be c Over-actions.

Diamond, Delta → Exotropia

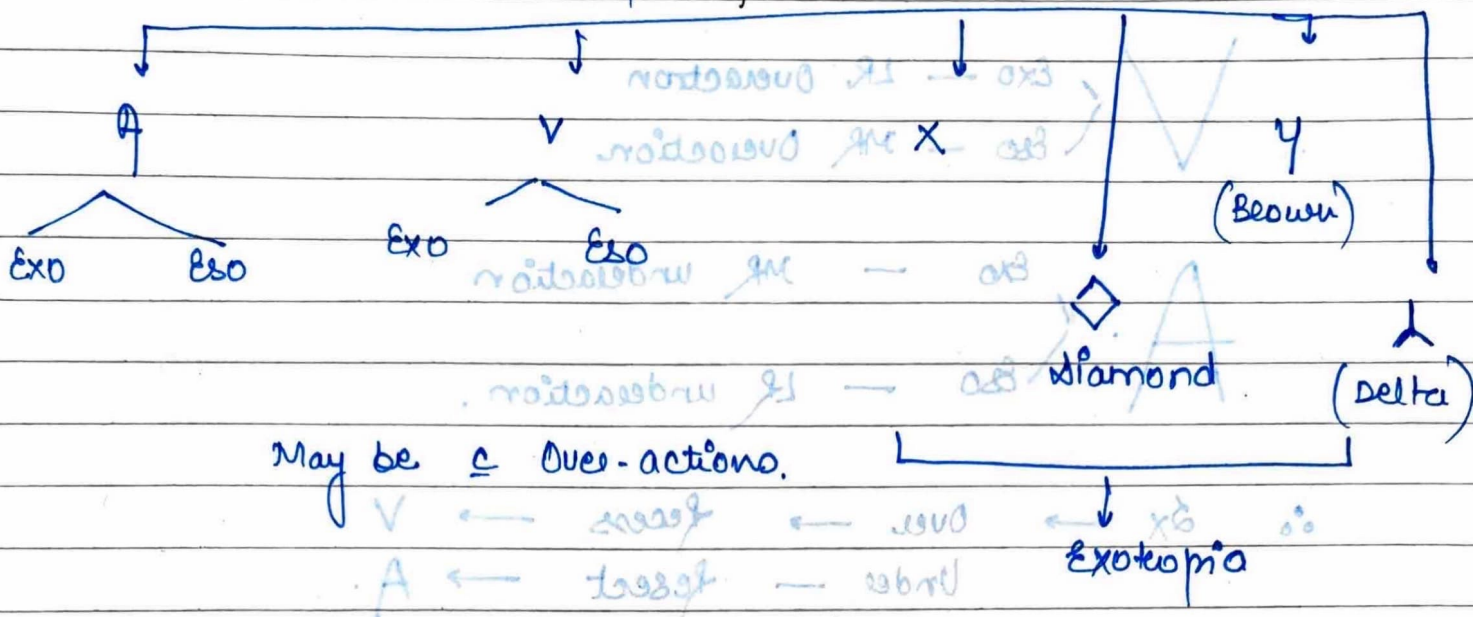

Prevalence

A — Exo → Indian.

V — Commoner. Eso → West.

Least Common → ◇ → of 4 → A Eso

Etiology

- Horizontal School
- Vertical School
- Structural factors.
- Anomalies of Mal insertions.



Horizontal school — Worst

LR ⟷ Upgage.
MR ⟷ Downgage.

V — Over
A — Under



Exo — LR Overaction
Eso — MR Overaction



Exo — MR underaction
Eso — LR underaction.

∴ Δx ⟶ Over ⟶ Recess ⟶ V
Under — Resect ⟶ A.

Vertical school — Brown, Cyclovertical school

A — SOOA.

V — 100A

Recti — Adduct.
Obliques — Abduct

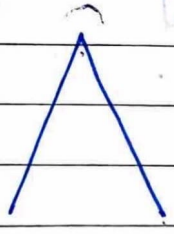

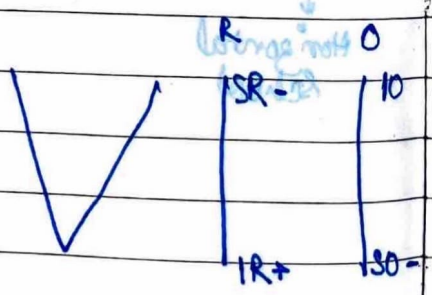

PAGE
DATE

Structural factors

Globin.

Sagittallization

Oblique becoming // to AP axis (Sagital)



(A)

(P)

frontally placed trochlea.

Hydrocephalus c frontal bossing

SO – strong depressor
IO – poor elevator

Desagittallization.

// to Coronal axis



Retroplacement of SO.

Eg Plagiocephaly

Poor ~~elevator~~ depressor — SO
strong elevator – IO

Anomalies of Mol insertion.





MR higher than LR
∴ Extract the globe

∴ Vertical shifting of horizontal recti

Diagnosis

Measurement
- Upgage – 25°
- Downgage – 35°

[Scale & protractor
Cephalodeviometer

- fundus Evaluation
- Head Posture.

A – 10 PD.
V – 15 PD

(C) Vertical Recti
Horizontal shifting ⇒ Very rare

Treatment

(A) +
↓
Weakening procedure / strengthening
(+)
Oblique

Oblique's Overaction / Underaction.

–
Only Horizontal recti (B)

- Exo – Weaken LR
  Eso – " MR
- Vertical transposition of Horizontal recti (b)
- Diff. Slanting

1° deviation ∝ Horizontal Sx
pattern ∝ Oblique Sx & (b)

MR (Eso)
- U End
- Inf End (more recession of)
  - A Eso
  - V Eso

LR (Exo)
- UE
  - V Exo
- IE
  - A Exo

Medial rectus shifted to APEX



(C) Horizontal shifting of Vertical Recti

- Y pattern. → Nasal shifting of Both SR.
- Λ. Delta pattern → Nasal shifting of IR.

(B) For Oblique Overaction

	10.	30.
Mild	6 mm recession	- graded recession
moderate	&	- " lengthening by
Severe	10	silicon expander
Markedly ↓.	+ AP. ⇒ Mod & & N.	
Very &	+ AP ⇒ Stager's	• Bilateral posterior Tenectom of SO → Mild-Mod
	Ant Nasal	Severe → Prieto Diaz procedure Translational recession of SO.

* Myomechomy

Superior Oblique Palsy. SO. Palsy
Trochlear Nerve Palsy

- Congenital
- Traumatic
  - Uni
  - Bilateral

Deficiency of depression in Adduction of involved eye.

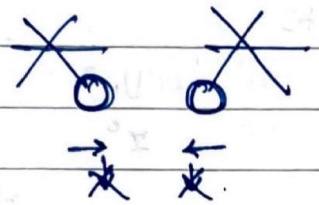

- Mild
  - Hypertropia in 3° position down & Adduction
- Moderate
  - Adduction.
- Severe
  - 1° also.

Long standing Cases

1psi 10 overaction,

Inhibitional palsy of Contralateral SR.

⇓

Hypertropia = in all gazes

- Double depressor palsy

Exam Head tilt towards Opposite shoulder

↓

To Correct excyclotorsion of eye.

To measure Excyclotorsion

Subjectively

- Double Maddox Rod
- Synaphophore ≤ torsion slides
- Field charting to note position of blind spot

Objectively

↓

Fundus Examination

Uni 7°

Bil 10-15°

>4° — Symptomatic if no Head posture

- Park's 3 step test / Bielschowsky's Test.

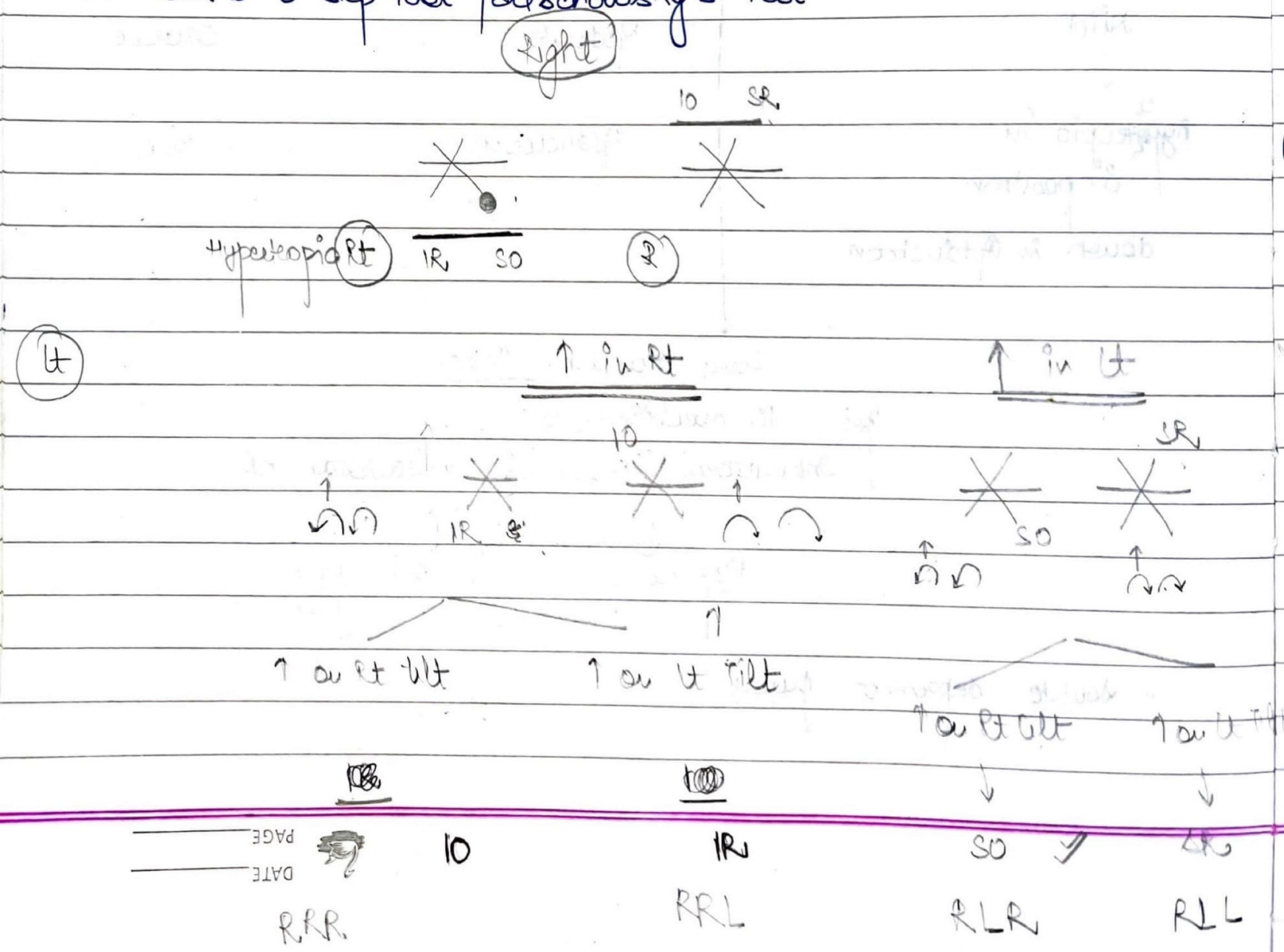

• Bilateral SO palsy features

- following closed head trauma
- subjective complaints of torsion. ⟹ Harada Ito Procedure
- objective torsion > 10°
- Alt hypertropia on alt head tilt. If no
- V pattern hypertropia
- Chin down head posture ↓ RIO recession

Management

Knapp's classification. — modified by Von Noorden

Class of max. gaze. RSO as Eg Mx. RIO recession

① Levoelevation

② Levodepression — RSO tuck + LIR recession (Modified Harado-Ito procedure)

③ Alt levo — Hypertropia
- < 25° ↓ RIO recession.
- > 25° ↓ RIO recession + RSO tuck

④ 3 + LIR/RSR recession
- Tight SR ↓ SR recessed
- Based on FDT Test

PAGE
DATE

5. 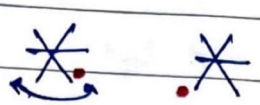 RSO tuck + LIR recession

6. Bilateral V pattern.  Bilateral IO weakening

7.  Explore trochlear & Levoversion.

down & I°

Bilateral SO palsy

↓

Harada Ito Procedure

SO is split — Ant fibres moved Ant & laterally — Incyclotorsion

↓

↑ Intortion power

Planes & Axes

	Plane	Axis	Movement
• Listing planes —	Horizontal	Z	Horizontal
• Ack's axis	Torsional	y	AP.
	Vertical	x	Vertical

Ductions — UniOcular

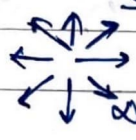

Sursum D

Excycloduction

Incyclo.

Deorsum D

Not affected by paraesis

Versions

Binocular eye movement

Conjugate → Version

Disconjugate → Vergences = useful as fusional

Con — Div

+ Vertical D −

In. — cycloV — Ex.

Agonist / Synergistics / Yoke mol



Hering law of equal innervation — for any movement the synergists receive equal & simultaneous innervation × followed in DVD

Sherrington law of reciprocal inhibition — Respective antagonists are inhibited to facilitate a smooth & unobstructed movement.

BRS

Horopter - imaginary plane on which corresponding points are projected

Panum's fusional area - a little area on either sides of horopter, which allows the sensory fusion despite disparity

else ↓ diplopia.

Squint

- Orthophoria.
- Heterotropia.
- Heterophoria → Latent squint.

a) Cause wise

- Concomitant
  - Horizontal
    - Exo.
      - phoria
      - tropia.
        - Intermittent
        - Constant.
    - Eso
      - Non Acc
      - Acc
      - ½ Acc.
  - Vertical
    - Hyper
    - Hypo
  - Torsional
    - Excyclo
    - Incyclo.
- Incomitant
  - Paralytic
    - Restrictive → Underaction.
    - Overaction
  - Spastic → Overaction.
  - $
    - Neurogenic
      - Supranuclear
      - Nuclear
      - Infra nuclear
    - Myogenic

Paralytic	Restrictive	Spastic
Underaction		Overaction.
1° & 2° deviation	2° > 1°	1° > 2°

Comitant = 1° = 2°

PAGE

DATE

Consequences of squint

- Confusion
  - 2 fovea & Image
  - ↓
  - foveal rivalry
  - ↓
  - Outer suppressed
- Diplopia
  - else →

Adaptations

- Motor
  - fusion
  - Head posture
  - Blind Spot Mechanism.
- Sensory
  - during stages of plasticity 6-7 yrs
    - Suppression
      - facultative
      - Obligatory
        - ↓
        - Amblyopia
    - Anomalous retinal correspondence
      - foveal & other extrafoveal point
        - Harmonious
        - Non Harmonious

b) Direction Wise

Esotropia
- Infantile.
- Accommodative
- Non "
- 6N palsy
- DRS Type I
- Thyroid Myopathy
- Stratismus fixus
- Mobius Syndrome
- Alt day Eso

Exotropia.
- 3N palsy
- DRS Type II, III
- Thyroid Myopathy
- Blind Eye
- Myopia

Hypertropia
- SO underaction
- Concomitant Hyper
- DVD
- Uni 100A.
- Double elev Palsy
- fibrosis of IR.
- Thyroid Myopathy
- # floor of orbit

c) Laterality Wise

Uniocular
- Alternate Squint

Binocular / Bilateral
- Rare
- Bil 6N palsy
- Moebius
- Systhyroid Myopathy

features of Alt Squint
- gen ∠ of deviation large
- Convg Squint >> likely alt
- Vision in both eyes near N.
- Error of refraction ↓
- Central fixation both eyes
- Amblyopia is rare
- × fusion
- ARC +

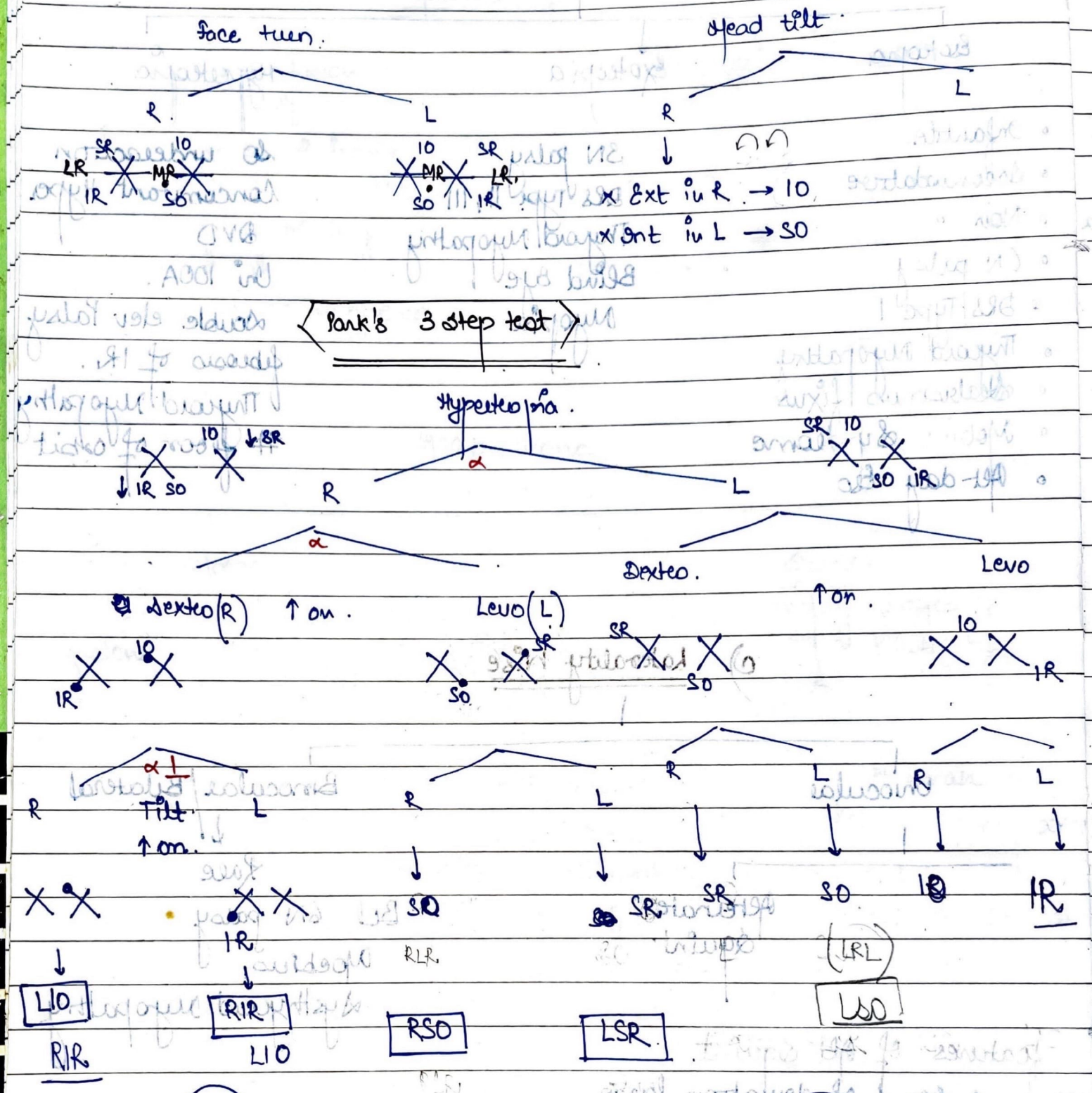

Bil

Ptosis + Tropia

Uni

- Congenital Ptosis
- Bil 3N palsy
- Myasthenia
- CPEO.

- Cong Ptosis
- Unil 3N palsy
- DEP c Ptosis

Head Postuee — Motor Adaptation

- Vertical → Chin elevation or depression.
- Horizontal → face tuen. Right or left
- Toxional → Head tilt.

Mech — ensuee that eye is out of field of actou of paralytic mal

Causes —
- Incomitant squints
- A or V patten. V Exo or A Eso → Chin Up (Max Movemⁿ)
- Nystagmus
- Refractive — Under corrected glasses or Wrong cylinder.
- One Eyed persons
- Homonymous Heminopia.

Ocular Torticollis — Head postuee in cases of Congenital SO palsy — Old photos.

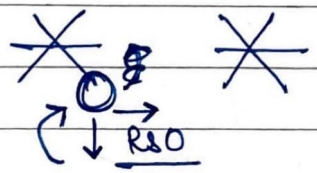

face tuen to opp side
Head tilt to ||
Chin depression.

a) Depressor — Chin depression
b) Intorter — Head till / opposite Shd.
c) Movement in adduction paralysed.
∴ abducted eye for Recti action.
Face tuen to opp side.

SCM → is not spastic.

PAGE
DATE

Measurement of IPD.

Uses

- Craniofacial disorders
- True hypertelorism vs Telecanthus
- Vergence Requirement.
- Proper centering of spectacles → Prismatic effect ↑ or ↓ existing deviation induce Squint ∴ eye strain.

How to measure IPD

- By Ordinary mm scale
- Using Pulgone Hardy Rule
- Using Synophophore.

PAGE

DATE

Pseudostrabismus

True squint – Misalignment of two visual axis, so that both do not meet at point of regard.

- P. Eso.
  - Telecanthus (IPD same)
  - Epicanthus
  - Blepharophimosis (Horizontally large palpebral aperture)
  - neg ∠ kappa
  - Myopes
- P. Exo +ve
  - Hypotelorism
  - Bilateral / Unil Canthoplasty
  - Hypermetropes
  - ↓ length of Interpalpebral fissure on temp. side.
- Vertical
  - Ptosis
  - Lid Retraction

Characteristics of Pseudosquint

- Often seen in children, may disappear ⊆ age
- Does not show any deviation Undercover
- Disappear if epicanthal fold is obliterated.
- Measurement of large ∠ kappa is demonstrable.

If Co-exist ⊆ True Squint → May worsen as Neutralge.

Angle kappa

Visual axis – fovea & target

Optical axis / geometric axis – Center of pupil

Normal = +5° angle eye looks Exotropic.
– To overcome optical abberations

>5°	< 5°
+ve	neg
Hypermetropes.	Myopes
P. Exo	Pseudo Eso

Obj – Measured by spl slide on Synaptophore.

Subj – Lister's perimeter in degree of arc.

Alt Cover test → direct^n of deviation
Amt " "
Speed of recovery
, MLN
DVD

Cover / Uncover → phoria vs tropia.
Unil vs Alternate.

↓

Phoria.

↓

If not ⟨ × phoria
Microtropia — special test

PAGE

DATE

Cover test / Uncover test

proper fixation target.
adult - 6m. Near = 33 cm.
child - Thumb / hand.

Alternate Cover Test
Cover / Uncover
Infant — Distant Cover test
Indirect Occlusion test

both eye fixate ✓
One eye fixate ✗.

Apparent δ.

Info

Cover → Tropia.
Uncover → Phoria.

- Type of Deviation
  - Eso
  - Exo
  - Vert.

poor recovery / poor fusion.
Speed of recovery & Strength of fusion

2) Alteration of fixation = Vision both eyes
3) Dominant Eye = Unequal vision.
4) Amblyopia.
5) Small ∠ squints except Microtropia

Pre-requisites

Ability of both eye to fixate the target.
Central fixation.
to have no gross / severe motility defect

Info 4m Cover test — Latent / Manifest / Pseudo.
Comitant / Incomitant
Unioocular / Alternate
Constant / Intermittent
Near / Distance
Magnitude

PAGE
DATE

PBCT

- Apex toward deviation
- Use prism for ↑ deviation

Alt Cover test
Prism Cover test

- Position of prism

⊗ for children
Restrictive squint

Frontal → // to Infra-orbital margin → Plastic

Prentice → ⊥ to line of sight → glass

- Causes of Variable deviation. (Dynamic) forces

Accomodative → Proper Correction — distant
Add — Near

Fusional Convergence → Occlusion of 4 hrs ↷ 24 hrs
(Intermittent Exo of Simulated Divergence Excess)

Static deviation & by Surgery

Dynamic forces glasses.

Deviation

↑ Minus lenses

↓ + lenses

$$\frac{MD}{AD} = 1 - 0.025 \times D.$$

- Split the prisms do not stack.

- Examination in 9 gazes

Diagnostic position < 25° Upgaze / 35° downgaze. | • Protractor/scale • Cephalodeviometer

- Deviometer – object moves.

- Diff aspects of Measurement
  - Distance — Near
    Eso/Exo ⊆ C insuff/D. excess or vice versa.
  - C glasses. — ⊆ out glasses
    Accomodative element
- 9 gazes — Motility restriction
  - 25° Upgaze — 35° downgaze
    AV patterns
- Right & Left eye fixating
  1° deviation. 2°
  - Subj. methods — Objective
    ARC determine
- After prolonged cover
  True divergence excess — Simulated DE Exoto
  & determine fully undissociated deviation.

Types of PBCT

Bruckner's Test → Infant, Unco-operative. toddler
Direct. Undilated.

Brighter reflex — Squinting eye

+ve → Microtropia
+nce of Amblyopia.

Also tell Error of refraction.
White reflex.

Crescent up
Hypermetropia
> 2mm

< 2mm — Up
└ Emmetropia



Inf - Myopia

Corneal reflexion test

- Hirschberg
- Bruckner's Test
- Krimsky
- Perimeter Test
- Amblyoscope (Synaphophore)

Hirschberg — Infants, Non Co-operative, Eccenteric fixation, Non fixation (blind eyes)

- Based on 1st. purkinje image.
-

Symmetrical → ~~Squint~~ ∠ kappa.

Asym. → ~~Angl.~~ Squint

$$\boxed{\begin{array}{l} 1mm = 5^\circ \\ 1^\circ = 2PD. \end{array}}$$



× for Microtropia

Krimsky — To Quantify deviation using prism bar
>> children.
>> In front of fixating eye.

Causes of Decentered Corneal reflex.

- Large ∠ kappa
- Tropia
- Ectopic Macula
- Eccenteric fixation
- Colectopia
- Coloboma iris

Subjective tests of Deviation.

- Diplopia testing principle
- Haploscopic principle
  - Ocular paralysis
  - Restrictive conditions

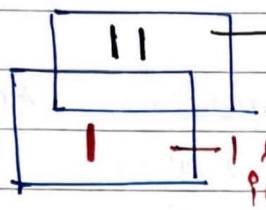



- Diplopia testing ⊆ Red green glasses
- Measurement of deviation on maddox tangent scale ⊆ help of Maddox Rod.

Subj — Polaroid dissociation. (May be foster)
- Lancaster Red green test.
- 2 foster torches ⊆ Red green filters
- Red green glasses
- Hess Red, green glasses
- Lees Screen Mirror Septum

Obj → Synaptophore

Diplopia Charting — Red green glasses.

Exo — Crossed — Heteronymous D

Image on temporal side of retina.

- illuminated slit
  - Horizontal
  - Vertical
  - Note the tilt

» Incomitant squint.

It to remember
- Max seperation in field of action
- Farthest image ∝ deviating eye
- Image displaced in direction of action of paralysed mol.
- Always document BSV gazes

- Diplopia type
- Type of seperation
- ↑ which gaze
- Mol involved.
- Tilt is in opposite direction to cyclodeviation of eye

RE — Excyclo — tilt Anticlockwise

Hess charting

1 square = 5° excursion
Inner squares = 15°

Analysis of Diplopia.

Is it real diplopia. or blurring of image.
- Running of image
- Jumping of letters

↓

Diff Diplopia from. Polyopia.
↓
Immature Cataract.

Closing eye.

- false/True Image
- Crossed & Uncrossed D

Horizontal
Vertical
- Skew deviat
- SD palsy
- Thyroid
- Myasthenia

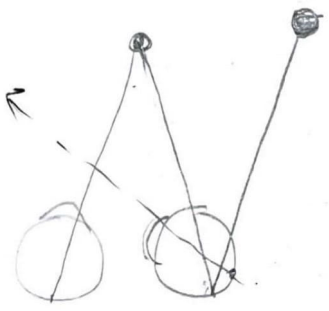

Eso

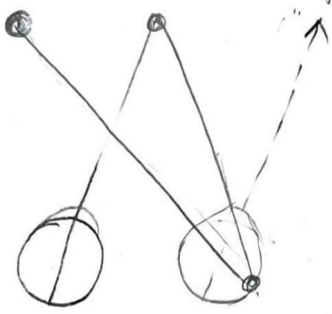

Exo

Subj Methods

Maddox rod
Wing
Tangent
Double Maddox
Hess Screen.
Red green glass test
Diplopia tests

Measurement of Cyclodeviation

Subj
- Diplopia charting
- Double Maddox Rod test
- Synoptophore
- Blind spot on visual field.

Obj
Indirect Ophthalmoscope

Indirect Ophthal



> 0.25 DD diff.



Double Maddox Rod

Limitation of Movemⁿ

Adduction — Normal when nasal ⅓ cornea crosses lower punctum

Abduction - Temporal limbus touch the lateral canthus.

Oblique Overactions

(10)

Mild	Hypers ↑ elevation	1	15°	
		2	30°	
Moderate	adduction	3	60°	
		4	90°	
Severe	1° position			



Painful Ophthalmoplegia → Tolosa Hunt Syndrome
Lymphoma "
Diabetic Oculomotor Palsy
Oculomotor palsy due to PCA Aneurysm
Myositis
Acq. Brown Syndrome.
Orbital tumours.
Parasellar "
fungal granuloma of Orbit

Measurement of Vergences

Vergences — determine capability of system to cope with an induced misalignment.

Vergence ↑ ↓ Squint ↑ ↓ Manifest ↓ ↑

Types

- Horizontal
- Vertical
- Torsional.

Horizontal, Vertical → Prism, Synaptophorce.

Horizontal

- NPC
  - Till double
  - Eyes deviate out.
  - Wear spectacle
  - Break pt
  - Recovery point of Convergence
  - c/u 3-5 diopter
  - 8-10 cm
  - >10
- NPA
  - Blur
  - Monocular
  - Binocular
- Convergence sustenance
  - ∝ assess strength of fusional reserves.
  - 45s - 1min.
  - <30s = Symptomatic Exo.

Prisms — 6m, 33 cm.

Break pt - Recovery - 3-5 D

» poor recovery as in Intermittent Exo who are symptomatic.

Di — BI

Order of testing

Conv ↓ → Diverg ↑

- Near point Ruler
- RAF ruler
- Livingstone guage.

	D	N
Convergence	14-20 PD.	35-40
Divergence	5-8.	15-20

Examination of Sensory Status

determines fxnal improvement
Cosmetic alignment] Prognosis

Assessment of binocular status — Nature of correspondence b/t them.

A •) Is Binocularity present
B •) Is there any diplopia — what type
•) Type of Correspondence
•) Is Suppression present — its extent & depth
•) Is amblyopia present.
•) Is stereopsis +nt, what grade.

A/B Binocularity & Diplopia

Diplopia

True — false — Blur

Binocular — Uniocular
- Astigmatism
- Subluxated lense
- Large PI.
- Corneal edema

How to dissociated eyes — Red, green glasses
Bagolini
Double Maddox Rod test

If x Squint or Squint cant diplopia — dissociation tells binocular status

Suppression

Sensory adaptation to squint where Only 1 eye fxn

- Unil
- Alternating
  - facultative
    - Binocular condition
  - Obligatory
    - UniOcular

Extent

Depth

Testing extent of suppression.

Supp. Scotoma — charting

- Prisms
- Synoptophore
- Lee's screen or Hess screen.
- Polaroid Scotometer

Depth of Scotoma
graded density filter bar
Denser — Scotoma disappear

Different Responses

- Less
  - Authorn. Phase difference haploscope
  - Polaroid Scotometer
    - 2 discrete Scotoma
    - A. foveal S. — 2-3° size
    - B. Diplopia point Scotoma
      - Eso
      - Exo
- Dissociating
- More
  - Prism, Lee's
    - Single Large Scotoma. A — B
      - Eso
        - Hemiretinal Scotoma
      - Exo
        - Discrete S.

A — showed vertical step like hemiretinal scotoma of Jampolsky

Type of Correspondence

- **Normal** — b/t fovea of one eye to fovea of other. → Bifoveal
- **Anomalous** → b/t fovea of one eye & extrafoveal pt of other eye

Test of ARC — • Age of patient
• Duration of Squint

Dx by →
- Bagolini striated glasses
- WFDT
- Synatophore.
- After image test (Hering Bielschowsky test)

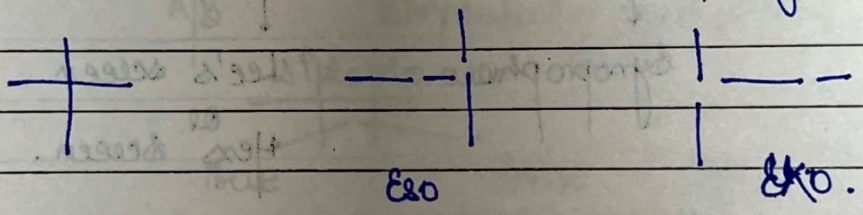

81

Bagolini striated glass

Most physiological

striation ⊥ axis of striations



× Manifest squint ✓

NRC

Harmonious type of ARC.



Incomitant squint ⊆ NRC

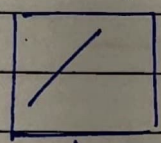

Suppression

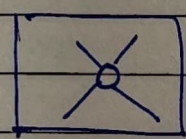

Central suppression scotoma.

If. not visible ⇒ use prism. then see crossed response i.e Subj ∠ (SA)

HARC ↓ UHARC ↓ NRC ↓

SA ✓ ✓

Zero *

Worth four dot test

» dissociating Bagolini . red green glasses

done at 6m. subtend 1·2°

If Scotoma > this size 1·2° ⇒ WFDT not visualized.

can be brought closer to ↑ L.

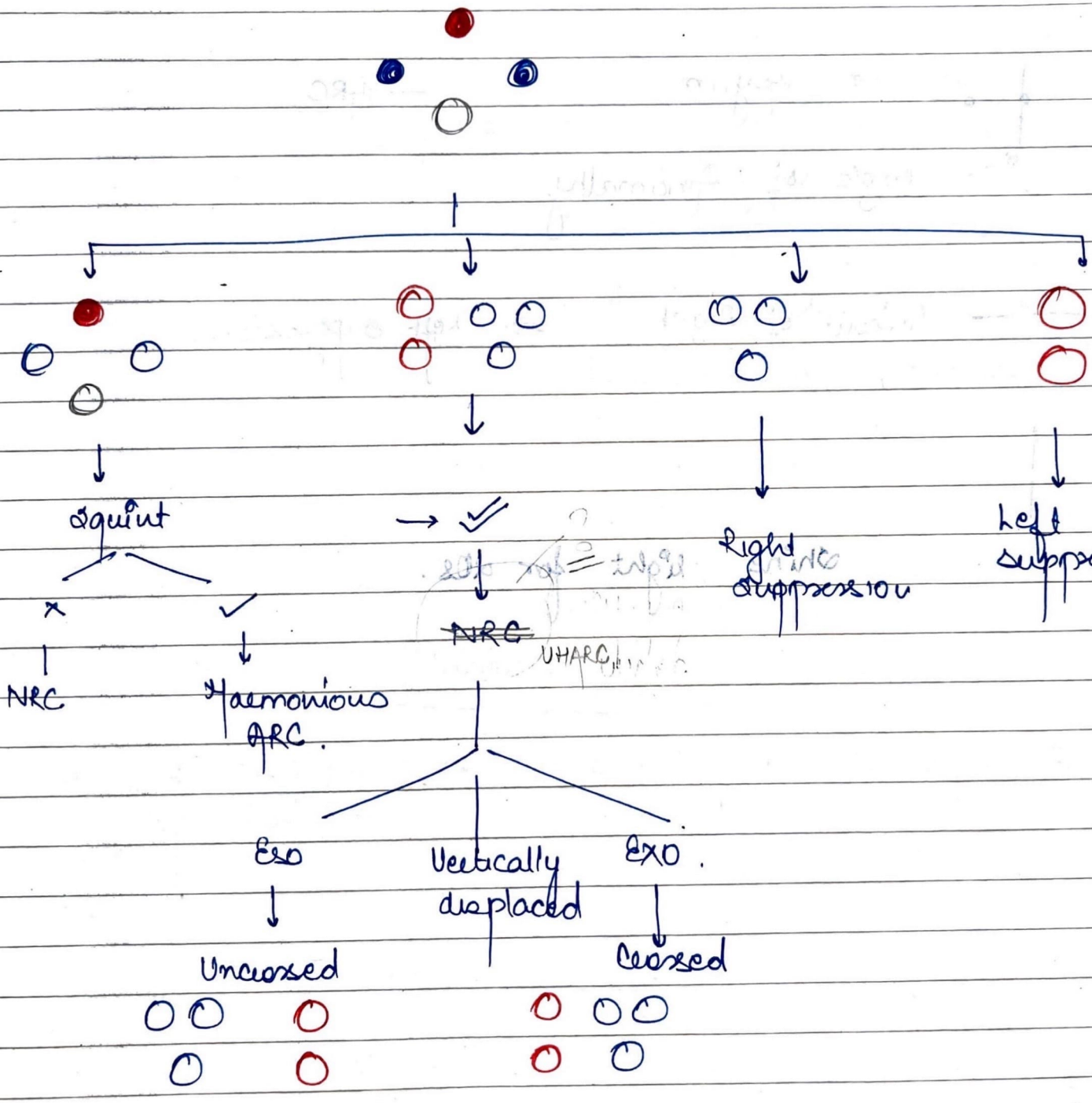

P1

After Image testing

Highly dissociating
RE — Horizontal
LE — Vertical

• Not physiological ∴ ✗ real picture always
⇓
Indicate deep rooted tendency of sensory status

—|— → Cross Response — NRC.



→ Asymm — ARC

Angle of Anomaly

— — Pursuit of Right ⇒ Left suppression.

|
|

Shine light for 20s.

Amblyoscope
Troposcope — Synaptophore

Orthoptic instrument based on haploscopic principle

- Chin rest
- forehead rest
- 2 tubes carrying target.
- Angled Eyepiece.
- Haidinger Brushes
- Target at fixed 6 to 6.5D

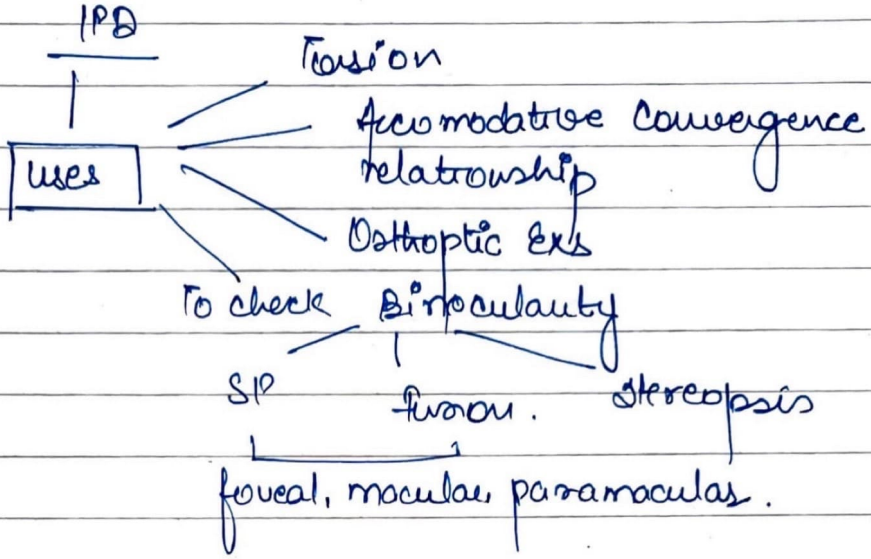

IPD

Uses
- Torsion
- Accomodative Convergence relationship
- Orthoptic Exs
- To check Binocularity
  - SP
  - Fusion.
  - Stereopsis

foveal, macular, paramacular.

Limitation

Convergence into play :. ? reliability to measure deviations esp horizontal.

Modifications

- S. of Cupax — Semitransparent mirror
- Of Oculus — measure deviation in peripheral positions.

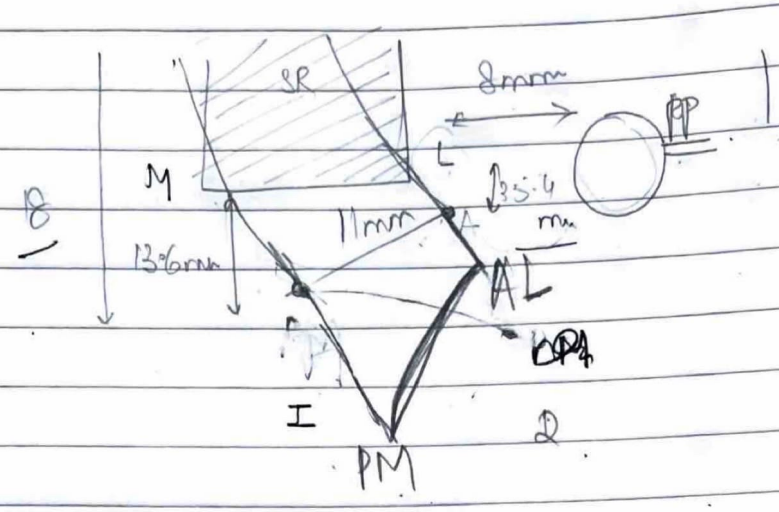

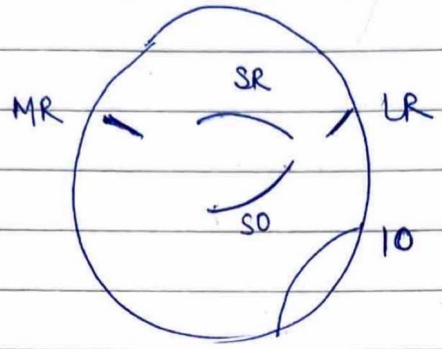



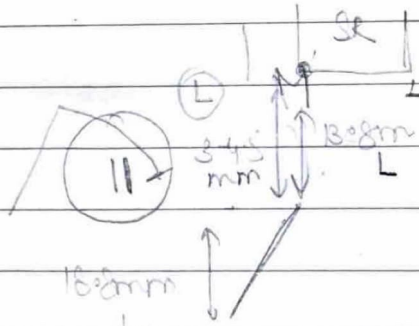

10

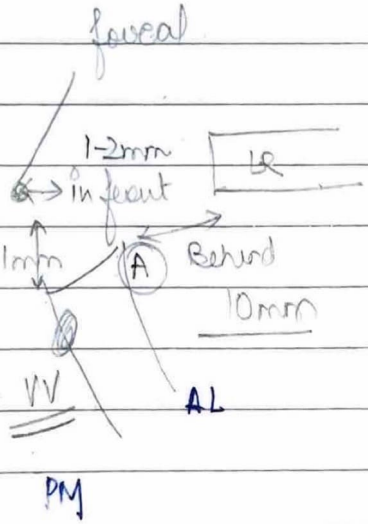

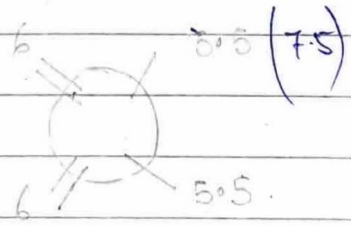

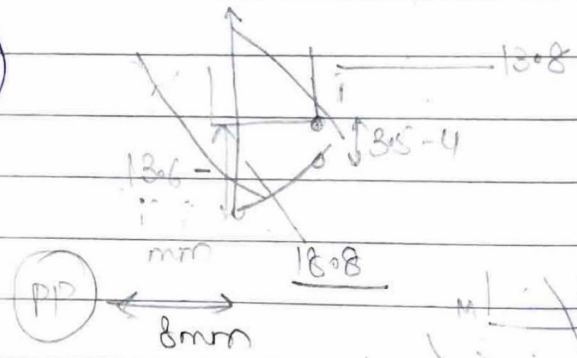

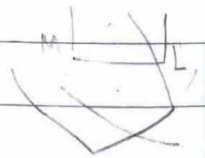

11mm

Sagittalizat^n
Se "

Superior Oblique

Anteronasal part of Orbit
Superomedial part of Optic foramen
Body of sphenoid.
run PL 100 - 105° to Vertical R Pathway.





// to Medial Wall upto Trochlea Insertion

Inferior Oblique.

Origin → Antero inf ∠ of Bony orbit in shallow depression in Orbital plate of Maxilla just lat to orifice of NLD Beneath IR.

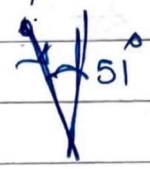

Trochlea — M — Trochlear fossa of frontal bone & L → Cartilagenous tissue.

Bursa is postulated 60mm.



Pre Trochlear — 10mm.
Trochlear — 4-6mm. | 40mm. ?
Post " 20mm

whole is msl.
No tendon.

37mm × tendon (1-2mm) shortest

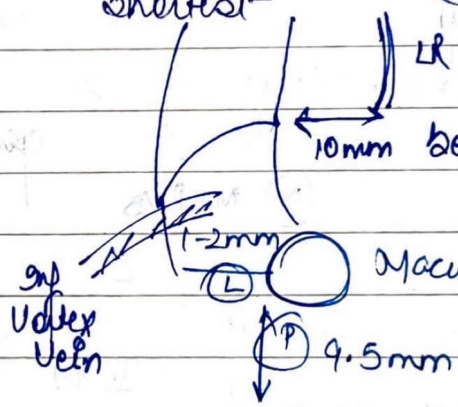

Optic Neuritis involved



fan shaped beneath SR

from SR Med end

from SR lat end.



i.e. 14mm behind limbus (13.8)

— Ant & Lat end — Intortion

19mm behind limbus (18.8)

Post & Med end

Depression

Longest Msl.



Shortest Msl.

Like others
enters from orbital surface d

Trochlear IV
enters from orbital surf divides in 3-4
diversion — A - P/3 M/3 P - 8mm from insertion
Intortor ∠ 1°

Blood Supply

Nerve Supply

as it crosses nasal border of IR (By also from infraorbital A

→ 4m bulbar side 15mm Origin

Actions

Ciliary & sphincter Pupil

Extortion

Add 54° depressor 2°
Abd 30° — Intortor

Abduction

Elevator extortor

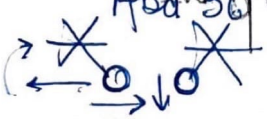

Superior Rectus — Inferior Rectus

Origin. Annulus of Zinn, surrounding Optic Canal & in part of
(*) Att to dural sheath at Origin ∴ Retrobulbar N

Path ← 23° →

Insertion Around spiral of Tillaux ✓

7.9 (7.75) Fuch's/Parson. 6.8 (6.6)

IR+10 = Lig of Lockwood

Recession – drooping of lid

Resection – narrow palpebral fr.

Bld Supply Inner aspect at jxn of Middle & distal third

Ant. Ciliary artery 2 — 2 also from Infraor tr

Ophthalmic A → Mol arteries { M: MR, IR, IO; L – LR, SR, SO, LPS

(N) M&P 1/3

(N) Enter Jxn of Middle & Post 3rd

Nerve Supply Superior division of III N — ciliary mol

LPS — Sphincter/dilator

by inferior

Actions 1° — Elevator — Depressor

2° — Intortor (superior) — Extortor

↑ ← (SR) → (SR)

23° Abd — elevator — depression

67° Add — Intortor — Extortion

Adduction

Talk about Yoke Mol.

Antagonist Mol

Medial Rectus.	Lateral Rectus.
SOF. →	→
(*)	
runs straight // to ‖ sagittall plane	40-45° Anterolat
curve around the globe strapping it. MR least	LR >>
5.3 (5.5)	6.9 (7)
ive	
(N) 15mm 4m origin	
→	→
ntal artery. 2 ✓ Also br from lacrimal artery	1 (Crucial)
] → Ant ciliary Arteries → 2 each, 1 LR.	Mol sx — Ant seg Ischaemia
from bulbar surface division.	Abducen 6th.
(1°) Adduction	Abduction
(2) depression ↓	↓
Elevation. ↑	↑

Upgaze

Downgaze

Tenon — Mal & Vortex vein piece

Extra Capsular → Mal sheath ✓

Intra Capsular ✗

Hering's law of Motor Correspondence.
states that · for an binocular movement the corresponding (yoke) muscle receive equal & simultaneous innervation.

⇓

Ensures Motor Correspondence

Symmetric Convergence — Asymmetric Convergence.

Normal Circumstances → Alignment in afferent gages

Abnormal Circumstances → Commitant squint = deviation.

✗ followed → DVD

1) Explain 1° & 2° deviation.
2) law of inhibitional palsy.

Sherrington law of reciprocal inhibition.

for any binocular movement the direct antagonist receives an equal and simultaneous inhibition of its innervation

for smooth movement — Antagonist need to relax.
Agonist to acts.

⇓

Law fails — Simultaneous contraction of Agonist & Antagonist

⇓

Co-Contraction allowing no movement.

Retraction of the globe.

⇓

Paradoxic innervation — Duane's Retraction Syndrome. ★

a) Why squint occurs

b) While Rx kept in Mind.

Donder's law — states that to each position of line of sight belongs a definite orientation of horizontal & vertical meridians relative to co-ordinates of space

3° position — Torsion.

Listing's law — Same thing there is no real torsion or cyclorotation of eye around AP axis when it comes to a tertiary position from a primary position.

(*) **IO** — In particular, innervation of msl occurs through NFVB, which attaches midway bt/ origin & insertion 2mm temporal to IR msl.

↓

After AP of msl, the NFVB ligament will mech act as msl's of new origin.

EOM

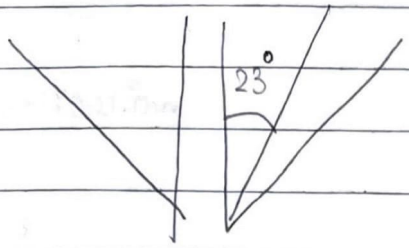

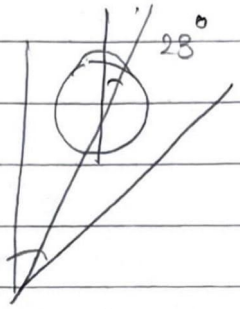

Recti Vertical insertion



Oblique insertion

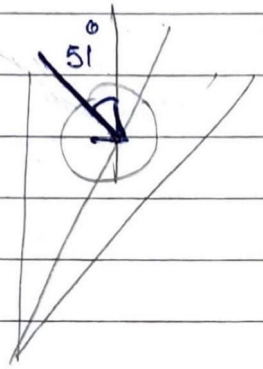

Action of Recti



Action of Oblique

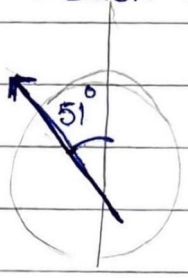



↑ or ↓

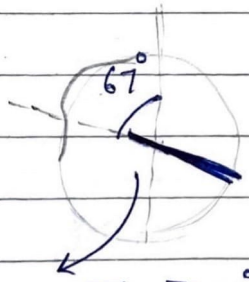

Torsion

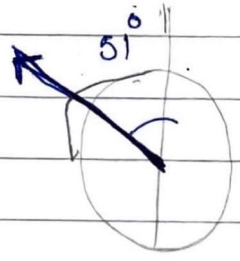

↑ or ↓

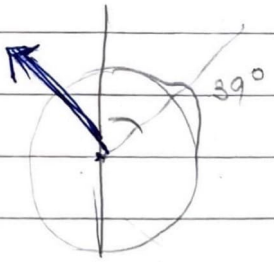

Torsion

Weakening Procedures on Inferior Oblique.

Indication.

- SO palsy
- V pattern deviations
- Double elevator palsy
- Upshoots in DRS ≤ 10DA.
- A/V S
- Other paralytic & restrictive conditions
- Torsional Kestenbaum.

Approach.

Skin (Bonnet) — Conj ↙

Incision.

- Limbal
- Fornix based
  - → good visualization
  - → ✓ LR along with

Technique.

Incision
↓
LR hooked
↓
IMSI septum dissected
↓
globe retracted in Supero-Nasal Quad
↓
Ant edge of IO can be seen underside of LR.
↓
2 cut ends held
↓
Reinserted

All recession affects Extortion

Reinsertion — (C)

Recession

Fink's method

Slacken's the mal.

Park's Method

Slight AP + R

R. of Ant fibres

Torsional Kestenbaum part

Weaken's Extortion (✓ ↑ & →)

R + AP

Modified E & N method

R + AP

× (↑ & →) in downgage

A&N transpose by stages

(C)

Denervation & Extirpation.

⇓

Overaction inspite of Maximal recession / Myemechomy

Myemechomy.

× obsolete

AP.

Pure

× R

× (↑ & →) in upgage

= 8mm of fink's

× effect on Extortion.

Total (E & N)

DVD ≤ 100Δ

× ↑ ✓ ↓

Finks

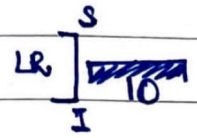



⇒ 6mm.

= 8mm pt

= 10 mm

Park's

10mm

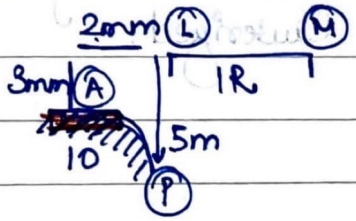

R + slight AP.

E & N

Elliot & Nankin's (Modified)

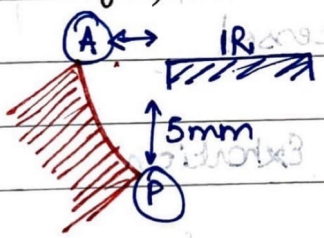



Ant & Nasal transposition by Stager's

R + AP

× Elevation & Abduction in down gaze

No Anti Elevation Syndrome (AES)

Pure AP



AP × R

- ×(↑ & Abd) in upgaze
- no effect on. Extortion
- = 8mm of Fink's

Stronger Weakening It causes AES!

Causes Antielevation Syndrome (AES)

- Hypertropia in Upgaze
- SO paresis ⊆ 25PS hypertropia.

Total AP | E & N procedure

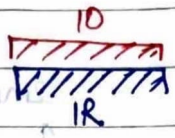

10 re-inserted to IR. Ant.

- (x Elevation at all)
- Some depressor action (as part of Lockwood lig)

Ix — DVD ≤ 100A

Denervation & Extirpation — Nerve to IO identified & Cauterized.

Recession of Ant fibres — Ant ½ of fibres 12-14 mm recessed

Weakens the Extortion

Same eye —— Opp

Adv of SO + Adv procedure (Weak IO)

Weak of SO + Str of IO ⇒ Part of Torsional Kestenbaum.

Strengthening of IO

Limited as it lacks tendon ∴ resection cannot be done it will be myomectomy ⇒ weakens

- double breasting
- 8mm advanced upward from its actual insertion

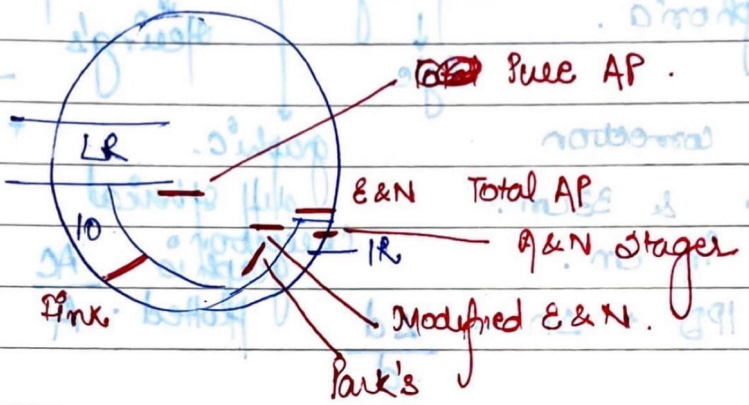

AC/A Ratio

Acc Convel — PD / Δ

Acc — D

Linear & stable throughout life

ID = 3-5Δ

Modified by Optical, Pharmacological, Surgical means.

Methods

- Heterophoria.
  - full optical correction at 6m & 33cm.
  - IPD in cm.
  - $\frac{AC}{A} = IPD + \Delta n - \frac{\Delta d}{d}$
  - d = fixation distance at near in Diopter
  - d = 3
- fixation disparity → Ogle
- Haploscopic → Hering's
- Gradient Method.
  - lenses → ↑ Acc
  - relax
- graphic.
  - diff spherical correction graph is plotted.
  - $\frac{AC}{A} = \Delta L - \frac{\Delta 0'}{D}$
  - ΔL = deviation c additional lenses
  - Δ = Original deviation
  - D = Power of deviation lens. (usually -3D)

Eso = (+)

Exo = -ve.

>>

Accn of proximal Convergence

changing distance of fixation.

∴ less estimation.

But Inaccurate as IPD not considered.

— at fixed distance

- 6m → Concave
- 33 → Convex

Classification of ExtraOcular Muscles.

Older

- Fibrillenstruktur
  - fine
  - fast twitch.
- Feldersteuktur
  - Thicker
  - Slow Sustained
  - ≤ multiple innervations.

New

(a) Location

- Orbital (mature last)
- global (old)

Colour

- Red
- Intermediate
- Pale

Innervation pattern.

- Singly
- Multiply innervated.

- Orbital (towards Orbit)
  - Singly innervated.
  - Multiply
- global (towards globe)
  - Singly
    - Red.
    - Intermediate
    - White
  - Multiply

PAGE

DATE

	OSIF	OMIF	GRSIF	GISIF	GWSIF	GMIF
	80%	20%	1/3	1/4	1/3	10%
Innervation	Single	Multiply				multiple grape like nerve ending
Mitochondria	Numerous (a)	↓	= a)	Numerous	few	few
Capillary	good supply					
	Myosin isoform profile	Central & fast twitch type	differ in isoform			
fatigue	- Most fatigue resistance mammalian skeletal msl fibre type	prox & dist & slow contracting	fatigue resistant.	intermediate level	Low	
Twitch.			fast	fast	fast	
					sporadically used	slow graded response

Embryological development

	Premandibular condensation	Maxillomandibular mesoderm
	↓	↓
6th W	III N	LR — 6 SO — IV
7wk	4 recti develop	
8wk	LPS differentiates from SR.	
3mth	LPS grows laterally on higher plane than SR	

EOM pulleys

Sleeves of collagen, elastin & smooth mol that encircle EOM & attached to Orbital wall & adj. Connective tissue.

Mol (sheath) ⟹ passes through these pulleys

Act as fxnal origin — located near equator of globe

deflect anterior part of mol in all gazes other than 1°

Adaptations to Squint

Motor	Sensory
• fusion	• Suppression
• Head posture	• ARC
• Blind Spot Mechanism	• Amblyopia.

• **fusion** — ability of eyes to check tedency to squint

Latent $\xrightarrow{Fx}$ Manifest

Requires Binocular input.

F Convergence >> Divergence.

Leads to Asthenopia.

• **Head Posture**

Chin elevation.

Face turn.

Head tilt.

• **Blind Spot Mech.** — In incomitant squint, 1° or 2° deviation is chosen by fixing with either of two eyes to take advantage of this mechanism.

Sensory adaptation

Young age

Confusion
↓
foveal rivalry
↓
suppression of image of other fovea

Squint ∠.

Small — Good.

Visual potential of extra foveal point

Large. — Constant, early childhood — Bad.

⇓

Suppression.

>> Visual ignorance. (upto any age)

ARC.

Establishment of a new working relationship between fovea of 1 eye and extra foveal point of squinting eye.

⇓

attempt to regain. binocular advantage.

⇓

fovea of other eye loses its property of 1° visual direction ⇒ Eccentric fixation.

shift of fovea to extrafoveal pt = ∠ of. Anomaly

ARC

Harmonious. | Unharmonious.

↓

Subjective re-adjustment of zero error

↓

Small angle of squint

O	Zero.	SA Subj. ∠	× O & < Obj ∠.
= AA	= ∠ of squint	OA · Obj ∠.	
HARC = OA − SA = AA			OA > SA.

Small ∠ squint,
Constant deviation
Young childhood.

» ~~Harmonious~~ physiological test revealed by » dissociating

→ Bagolini striated → Synaptophore
→ Red green glasses

NRC = OA = SA AA = O.

AA

= OA > O	O	> O . ≠ OA
↓	↓	↓
HARC	NRC	UARC

Pre-requisite of ARC — Early Onset
Constant angle of deviation.
Small Esodeviations.

Diagnosis

OA — SA

PBCT
Cover/Uncover
Synaptophore

ASWMPPB

dissociating

Most — Least

After image test
Synaptophore
Worth 4 dot
Maddox rod or Red filter
Polaroid dissociation
Phase differentiation haploscope
Bagolini stelated

Eso — Single Large Scotoma. — 2 point Scotoma.

Correspondence

Fine level. — Coarse level

More physiological real situation

Less dissociation test

HRC

dissociation.

UHARC

Hyperacuity

Capability of human eye to see more than ability of retinal cones to resolve

⇓

Due to involvement of higher cortical centre in the parietal cortex

- Vernier Acuity
  - 10-20 arc sec
  - Seperation b/t 2 lines not in perfect alignment.
  - grating acuity
  - Vernier acuity
    - ↓ in amblyopia
- Stereoacuity
  - 16s
  - Depth perception.
    - ↓
    - PLT by 6mth.

Stereo-acuity tests

Haploscopic principle using 2 two dimensional or vectographic pictures.

Disparity in 2 picture creates 3D image

- Synoptophore → stereopsis slides
- TNO test → Red green goggles
- Randot stereotest & litmus stereotest → Polaroid glasses
- Lang's stereotest → x glasses ⇓ Panography ⇓ Prismatic film. laminated R L → Children
- Special 3D pictures

Rudot stereotest – geometric shapes
polaroid glasses
uses Julesz's random dot background to mask monocular clues
40 cm. ∴ near binocular vision
✗ → Myopes upto 5D can be missed
consist of random dots × contour pattern.
∴ no lateral displacement cues.

× cues.
Effective screening

TNO test – Based on random dot background.
7 plates – I–III – 1980s – gross
IV – suppression plate
V – VII – qualitative plates
If fail pass ⇒ V ⇒ screening
40 cm distance

✓
Children
3yr old
screening tool

✗
near stereopsis
red & green.

Wist's circle 400 arc sec - 20 arc sec.
TNO 480 - 15 arc sec
Feisby 600 AS for 30cm viewing
300 AS
150 AS

Adult = 40s or > 8yr.
3-5yr = 70s
5-7 = 50s

Lang's two pencil - 400 arc disparity
Titmus fly 3500s
Stereo Butterfly Upper wings 2000s.
Lower wings 1150s
Abdomen 700s.

Frisby test

3 perspex plates of different thickness

6mm 3mm 1.5mm

4sq = 3 full of △ & 1 empty

600 300 150 Asec for 30cm.

Distance. stereoacuity — diminished stereopsis for distance ⇒ early sign of Exophoria

- Frisby Davis distance FD2
- Randot ↓ 8m.

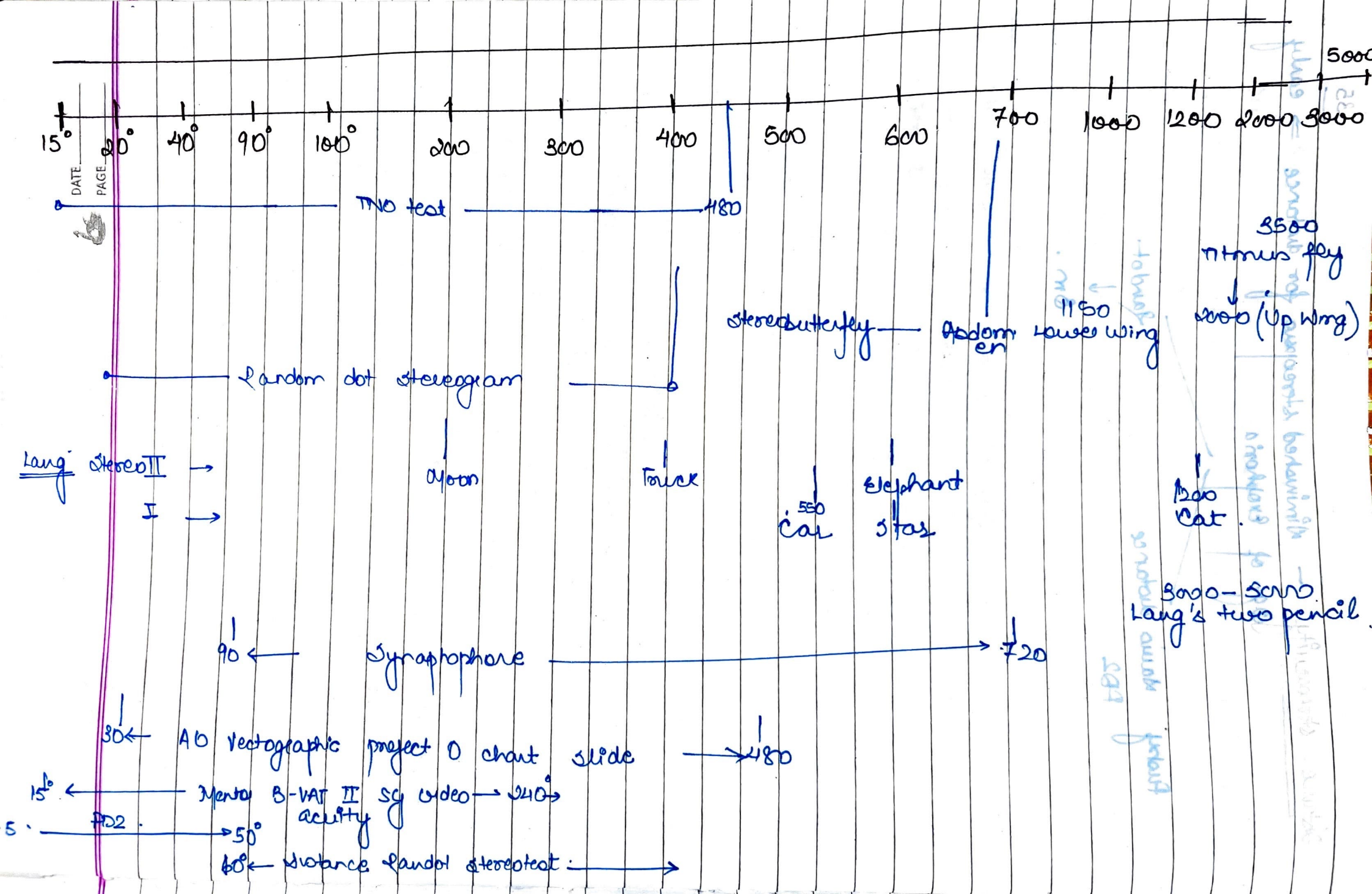
15°
20°
40°
90°
100°
200
300
400
500
600
700
1000
1200
2000
3000
5000
DATE
PAGE
TNO test
1180
3500
Titmus fly
2000 (Up Wing)
Stereobutterfly
Random dot stereogram
Lang Stereo II
I
Moon
Truck
Car
550
Elephant
Star
Cat
1200
3000 - 5000
Lang's two pencil
90
Gyrophore
720
30
AO Vectographic project O chart slide
180
15°
Mentor B-VAT II SG video
240°
acuity
5°
FD2
50°
60°
Distance Randot stereotest

Classification

Based on distance

Near.

- TNO test
- Titmus fly test
- Stereo. Butterfly test
- Random dot stereogram.
- Lang test.
- Lang 2 pencil test
- Stereopsis slides on synaptophore.

Distance

- AO Vectographic project-O-chart slide
- Mentor B VAT II sg video acuity tester
- Fusby Davis distance. Stereoacuity
- Distance Randot stereotest

Based on Principle

Haploscopic

∠ mirror in front of eyes

Rt temporal — Lt Temporal

⇓

synoptophore

Anaglyph.

using colour red & green.

TNO test

Vectographic

polarized light direction & other direction

x. red, green tint.

Titmus fly Randot stereopsis test

Panorgraphic

grid of cylinder c random dots in its pattern.

Lang's.

Titmus stereo test — Vectographic
Contains pattern 45, 135°
stereo fly card, polarized glasses
3yrs onward

✓
- effective screening of gross fine.
- monocular clues

×
- near
- Lateral displacement cues

Stereobutterfly — UWings — 2000s.
Lower — 1150
Post — 700s.

Lang test —

Stereotest

I
- Star
- Cat
- Car

II
- Moon
- Truck
- Elephant

Star — can be seen by 1 eye.

✓ Cheap test.

100% Sensitivity
neg predictive value

✓ Easily performed
× No material
× polaroid & red green

BSV

- grades
- Horopter
- Panum fusional area
- Theories
- development
- Amblyopia
- Suppression
- ARC
- Test.

Theories

1) Theory of Correspondence & Disparity
   ↳ Neurophysiologic basis of Correspondence

2) Older —
   - Alternation theory
   - Projection theory
   - Motor theory
   - T. of isomorphism.

Esotropia

Pseudo – due to telecanthus or epicanthus.

Types of Esodeviation

- **Incomitant**
  - **Paralytic**
    - Neurogenic
      - Abducen palsy
      - Divergence palsy
    - Myogenic
      - Myasthenia
  - **Restrictive**
    - Musculofacial (Duane)
    - Other restrictive conditions
      - Tx
      - Dysthyroid
      - Fibrosis fixus
  - **Spastic**
- **Concomitant**
  - **Accomodative**
    - Refractive
      - Hypermetropic
    - Non Refractive
  - **½ Accomodative**
  - **Non Accomodative**
    - Essential infantile
    - " Acquired
      - Basic
      - Conv Excess
      - Diver insuff

- Acute Concomitant
- Mucoteopia
- Cyclic Esoteopia
- Sensory "
- Nystagmus Blockage Syndrome
- Esophoria

a) Essential Infantile Esotropia

Till 4mths eyes in flux. ⇒ Orthotropization curve in that period.

⇓ Initally eye in Exophoria/tropia.

∴ Till 4mth no. Comment.

Characteristic

- Large angle Esotropia ×30PD
- Free alternation.
- No Refractive error.
- No Neurological deficit
- Confirmed by 4-6 mth
- Ass C
  - 100 A 68%.
  - DVD 50%.
  - Nystagmus 33%.

- Asymmetric Optokinetic Nystagmus → T→N smooth, N→T Cogwheel — ?

Types

- Ciancia
  - Eso + Bil. limitation of Abd + MLN ↑ ⊆ Abd
  - face turn toward fixing eye
- Lang's
  - DVD, Nystagmus + Excyclodeviation of non fixing eye.
  - ⊆ torticollis.

D.D

- 6th N palsy — Doll's Eye Movem
- Duane's DRS — Retraction, Palpebral aperture Ht, Downshoot/Upshoot on adduction
- Down Syndrome / Mobius Syndrome
- CP
- Albinism
- NBS
- Acc Eso → Cycloplegia.

Phenomenon of Saccadic Movements

Underaction of Saccades of Uncovered eye.

Alternating Esotropes — Amblyopes

↓

1- S. — Normal — N Eye fixate — Underaction ✓

Previous Eye — Underacting — Amb Eye fixate — ✗

LR palsy (Acquired squint)

⇒ Saccades of LR show paresis irrespective of which eye fixates

Mx

full cycloplegia

↓

full correction (Over Correct)

↓

Amblyopia — Inability to test VA. — Unilateral preference of fixation. — Resistance to allow covering of 1 eye.

↓

Occlusion. → Conventional full time fully opaque.

days/wk ∝ yrs of age

after 6. ⇒ Continue 6.

⇓

Alternators — still continue to ↓ temporal nasal bias → Sx.

Sx

- Larger ∠ → Rx
- Small ∠ → Monitor 4-6 mth.

MR : LR = 3 : 2

- 3-4.5 PD (4D)
- 2-3 PD (3D)
  - Conv Excess → Bimedial recession.
  - Divergence excess → Recession, resection. Sx
  - Insuff

Post op Results — Von Noorden.

Optimal goal.	Desirable goal	Acceptable goal.	Unacceptable goal.
BV — Subnormal			Suppression +
Ortho.	Microtropia	Small ∠ Eso.	Large ∠.
VA — N			
RC — NRC.	ARC.	ARC.	
Stability ✓	Some.	↓ stable.	
Rx.	only for Ambl.		Resx. Prism & glasses

⇒ Botulinum injection in MR.

PAGE

DATE

D) Accomodative Esotropia.

Eso due to excessive Convergence + accomodation.

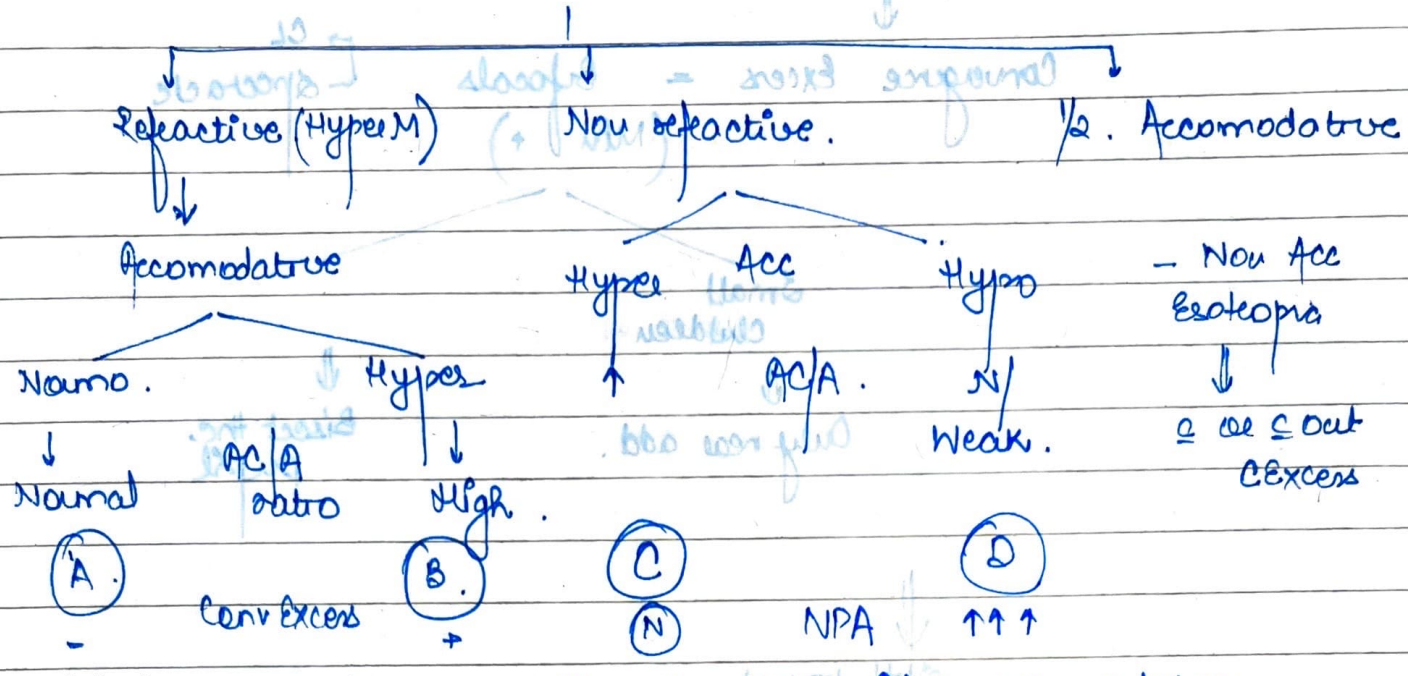

Clinical Presentation — Variable Eso, ↑↑ ≤ accomodation.

(A) — ✕ Convergence Excess
Esotropia. ↘ Amblyopia ↘ Asthenopia
Mild to moderate | +2 to +6 D.

$\Delta D = \Delta N$.

$\Delta N > \Delta D$.

(B) — Conv Excess
even residual ≤ full Correction ∴ bifocal for near

(C) — ✕ Hyperopia ↑↑ AC:A Ratio ✕D. ✓ ΔN

(D) NPA, NPC ↑↑
Conver Excess
like early Presbyopes / under mild cycloplegics.

PAGE
DATE

Mx

full cycloplegic Rx

a) glasses

Over Correct

Convergence Excess = Bifocals (Min +)

CL

Spectacle

Small children

Only near add.

Bisect the pupil

Still persist

Non Accomodative pattern.

d) Sx.

b). Miotics

x → Headache, Nausea, Abd Cramps

Ocular → Ins. cyst, ACG, Lens Opacities, RD.

→ Ecoltriophate – 0.03%. 1 drop OD

0.125%. BD.

→ Di Iso. fluorophosphate Oint

c) Small residual Deviation – Prism

d) Non Accomodative part – MR recession. c or c out faden.

Acquired or Late Onset Non Accommodative Esotropia

Eso after infancy
≤ accomodative factors
x Neurological Cause

⇓

Acquired Non Acc Eso.

- Basic type
- Div Insuff
  ↓
  x Div palsy.
  as ↑ Has Neuro Cause
- Convergence Excess

℞ — Surgery.
good visual potential.

→ Miotics produce accomodation peripherally by direct stimulation of ciliary mol — which will reduce need for central accomodation ≤ its associated Convergence.

Microtropia

Ultra small ∠ Esodeviations
└ usually ⊆ Amblyopia
Variable levels of binocularity

1° 2°
↓
after Sx

BSV ⊆ fixation disparity → Small ∠ Esotropia

Types 1°

Park's Monofixation Syndrome.

- Macular Scotoma.
- good peripheral fusion
- fusional amplitudes
- gross stereopsis

Lang's Microtropia

<5° Heterotropia
Harmonious ARC
Mild Amblyopia
½ - stereopsis

Type I → Central fixation.

II → Eccentric fixation
⊆ out ~~disparity~~ identity.

III → True Microtropia

⊆

⇓

AA = eccentricity of fixation

Cover test ✓ ✓ ✗

Findings

Consistent	Variable.
Amblyopia.	Size of deviation 5-8°
ARC	Foveal / non foveal fixation
Relative scotoma.	° of eccentric fixation & AA.
Normal fusional Amplitudes.	Anisometropia. +/-
Defective stereo-acuity	Cover test +/-

Dx

- Amblyopia
- Associated refractive errors.
- Bagolini — Macular scotoma. #
- 4PD. BO Prism test #
- foveo-foveal test of Cuppers.

Mx

℞ Amblyopia by occlusion.

4PBO — Normal — refixation movement
Micro — ✗ → weak fusion ⇒ diplopia

PAGE
DATE

Acute Concomitant Esotropia

✓ Diplopia

I

- 8-C fusion has been Interrupted by patch or occlusion for short time.
- good fusional controls

II

- Interruption to fusion
- Poor fusional control compromised by physical & emotional stress.

Swan type → Occlusion

Francescletti → Convergence

Bielschowsky → Hypopia

Ix for Neuro Cause → Look for Neurological cause

I → follow x 6mth

II → Dx.

cyclic Esotropia

24-48hrs of squint days → No squint days.

Sensory Eso

1 yr — Exo

in b/t — Eso

8-9 yr — Exo

Nystagmus Blockage Syndrome.

Esotropia ↙ MLN
↘ MN

If. Nystagmus $\propto \frac{1}{\text{Esotropia}}$.

Nystagmus ↑nt when. straight
& ↓ if Esotropia
i.e dampening mech. ≤ eyes in adduction.

Exotropia

Rare due to fusional convergences
If Essential infantile Exoteopia — rule out neurological cause

Types

- Cocomitant
  - 1°
    - Infantile Exo.
    - Intermittent Exo
  - 2°
    - Sensory Exo.
    - Consecutive Exo.
- Incomitant
  - Paralytic
  - Restrictive
  - Malfacial anomalies
  - Diss Horiz Deviatⁿ.

Duane's

- Divergence excess
  - $D = 15\,pd + \Delta N$
- Convergence insufficiency
  - $N = 15p + D$
- Basic Exodeviation.
  - = c in. 10pd.
- Simulated divergence excess / Pseudo DE
  - Tenacious proximal fusion
  - Δn = compensation by fusional C
  - after patching eye

On basis of fusional reserve.

- Exophoria (XP)
- Intermittent Exoteopia (~~XP~~) X(T)
- Manifest Exoteopia XT

Clinical features

Essential Infantile Exotropia

1° C. Exo that lack binocularity

Essential → x Craniofacial abn.
Neurological disease
Restrictive syndromes
Vision impairing ocular defects

- Large ∠.
- Alternation.
- Early Onset.
- xx Amblyopia if ✓ — Anisometropia
- Race ∴ rule out neuro cause

Intermittent Exo — Most Common
Intermittent
May go into suppression
» Asthenopia
Diplopia phobia ⇒ discomfort due to strong light
» Micropsia.
Abnormal stereopsis ∴ Intermittent ↷ Manifest

Sensory Exo. due to Poor vision in 1 Eye — OA.
Macular Scars
Dense Media Opacities

fusion free positions

Consecutive Exo. - Post Sx

Natural H/O of intermittent Exo

IDS not Rs → Constant DS

Unil. / Alternating

α. Unilateral preference of 1 eye.
free alternation

α fusion — α. general health
alertness.
attention span.
level of anxiety.

Factors to be recorded for Progression.

- Loss of fusional control
- Development of 2° CI. (convergence insuff)
- ↑ in size of basic deviation
- Development of suppression

Phase of Exo & clinical presentations

Calhounz et al -:

	D	N	Symptoms	Detected
•	Exotropia	Ortho.	x	Un.
•	IExo.	Ortho, Exophoria.	for distance	
•	Exotropia	Exotropia or IE	- Suppression Scotoma. for D - Binocular Vision for N	
•	Exo	Exo	x Binocularity	

Imp

Sensory adaptations in Exo.

- Rare. as its Intermittent
- ∴ × Strabismic Amblyopia may be due to other cause

» Suppression ↔

Large → Suppression

Small ∠ → ARC.

Dual Binocular Behaviour

less —dissociating→ High

less → 2 discrete Scotoma

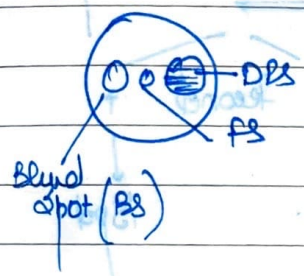



High → Large Scotoma fovea to diplopia point & a sharp nasal cut off. (Hemiretinal suppression of Jampolsky)

Magician forceps Phenomenon

Reverse phase reflex. → Opp movenⁿ of other eye when 1 eye passively moved in any direction.

MFP — On passive adduction of dominant eye, Exo of other eye gets corrected or straightened.

Mx

Non Surgical

✗ alter angle

Orthoptic

Glasses

Overcorrected Concave lenses

⇒ ↑AC : A ratio

Anti Suppression Exs.

∝ diplopia recognition

Sup for distance

BSV by Anti Suppr Exs

- Bar reading
- Synoptophore
- Cheiroscope.

Convergence Exs

Fusional ↑ phoria

1st step.

Train to ↑ both.

phasic

Tonic | control.

start ⊆ Synaptoph.

⊆ Home Exercises

Prisms Bi prism

- Fresnel +

8pd. 15pd

SHOT

40s, 5s break.

for 3-5min BD.

Conv Trainer

N

fuse

Surgery

Ix

> 50% of waking hrs
Phase II, III of Calhoung
Suppression Scotoma. +nt
Diplopia phobia
× Diplopia ↷ Suppression
Phase IV → Sx is of Cosmetic Value.

Timings

Knapp — Early
Jampolsky — Late
New Castle Score

Home Control

Interm. Exophoria or Monocular Eye closure

Never	0	
<50% time for distance		1
>		2
>	D+N.	3

Clinic Control

Distance	Near
Immediate realign.	
after Cover Test — 0	0
after blink/reflex — 1	1
No. Realig/Manifest Spout — 2.	2

Total NSC
>3

Choice of Sx — Comparative deviation at 33cm, 6m.
AC:A Ratio
Change of deviation of Lateral Version.
A, V phenomenon.

Bilateral Symm Sx

- True Divergence Excess
- Exo ↓ on Lateral version
  ∴ ↓ Sx req
- V when 10 has to be tackled ⇒ same Conj approach
- If x DOA then for vertical shifting of horiz. secti.

Unil R & R
↓
Basic Exodeviation

Amount of Correction

<5yr	> 5yr	Adult
↓	↓	↓
× Over Correction	✓ Over Correct	diplopia for distance
	↓ To stimulate binocularity	

Mx

BeOp	Post Op
• Rx refractive Error	Undercorrect
• Rx of Amblyopia	
• Rx to eliminate suppression at divergent ∠	Over Correct
• Max ∠ of deviation determined — Occlude for 1day ⇓ determine.	

Etio theory — Mechanical (Bielchowsky)
Theory of defective fusion (Wolth)
Hemibetrhal suppression (Krapp & Jampol
Uncorrected RE (Sonders)

Comitant		Incomitant
Early childhood.	Age of onset	Usually late
gradual/sudden	Type of onset	sudden
x	Pt events	Usually head injury
x	Associated Neuro Signs	✓
Usually not extreme gazes	Comitance	May develop in late. stages
-	Acute onset or decompensated (exc. exophoria)	diplopia. +
-	Head posture	+
x (except DOA A-V pattern)	Cycloteopia	+ (x ≤ Horizontal gaze palsy)
+	Sensory adaptations	-
x	Past pointing	+ in. recent cases
gradual -	Symptoms	+/-
+	Hereditary	+
Variable, may be cause	Vision	unrelated
May cause deviation	Error of refraction	-
Normal	Movements	Restricted
x	2° changes in Mod	✓
	1° & 2° deviation	2° > 1°
x.	Spontaneous recovery	✓
x	change to Comitance	✓

Paralytic Squints

Incomitant Squint

Misalignment of two eyes which varies in different gazes or in other words the Ocular deviation is different in different gaze positions.

Types

- Paralytic / Palsy
  - Paretic
  - Paresis.
- Restrictive
- Spastic

Paralytic Strabismus — An incomitant squint due to motor def of 1 > more group of EOM

Restrictive	Paralytic
1° > 2°	2° deviation > 1°
Not ::	Limitation : Ocular deviation
>> affected	=
✓	AFGT Tug Weak
normal	Saccadic Velocity slow.

Classification

Paralytic Squint

- Neurogenic
  - Supranuclear
  - Nuclear
  - Internuclear
  - Infranuclear
    - Fascicular
      - 3
      - 4
      - 6
  - N-M Jxn.
    - Myasthenia.
- Myogenic
  - Mal
    - Congenital
    - Traumatic
    - Inflammatory
    - Oculo-myopathy
    - Dystrophy

Causes:

- Congenital
- Traumatic
- Inflammatory
- Neoplastic
- Ischaemic
- Toxic
- Demyelinating.
- Idiopathic.

PAGE

DATE

Clinical feature of Paralytic Squint.

- Incomitant — Variable Ocular deviation. Max in field of action of muscle.

		fixing	Deviation
• Limitation of Movement	1°	Normal eye	Squint
• diff in 1° & 2° deviation.	2°	Squint	Normal

2° > 1° because » effort to bring squinting msl in 1° position ∴ » d. supply to Contralateral synergist/yoke msl ∴ ↑ deviation.

⇓

Long standing → Spread of Comitance.

Stages of Paralytic Squint —

1st — Maximal deviation in field of action of paretic msl
LLR deviation »» Levoversion.

2nd — Overaction of ipsi Antagonist.
LMR. D » ~~Dexteo also~~ 1°

3rd — Underaction of Antag of (contralateral synergist) Yoke Msl.
Inhibition Palsy
RLR. D » Levo → 1° → Dexteo

⇓

? Paretic ∴ Patch / Occlusion test

⇓

If paretic eye is occluded (24hrs)

↓

Inhibitional palsy goes.

Examination of Paralytic Case

- Relevant H/O → Age of Onset
  Type
  Pt event — fever, Head injury
  Associated Neurological signs

- Past Pointing
- Measurement of deviation
  - Ocular
    - Cover test
  - Subjective
    - Maddox Rod.
    - Diplopia charting — Always m BSV
    - Hess / Lees charting

- Newton BSV gages.
- FDT
- AFgT
- IOP in different gazes
- Saccadic Velocity recording
- EMG
- NO fundus exam.

Mx of Paralytic Squint

- Paralytic Workup.
  - Non Surgical
    - Occlusion.
    - Prisms — only for small ∠.
      ↓ chance of Contracture develop.
    - Botulinum Injection.
  - Surgical — Weaken Antag
    ∠ restrain Contral Antag

Past pointing — Recent Onset.

Septum — × Visual feedback.

farther perceived & extra innervation req by hand for pointing

FDT (Forced duction test)

fallacious in innervational anomalies if done in relaxed mal.

Checks restrictive element

- Paralytic → due to Contracture (Long standing) 2nd stage of Ips Antag
- Restrictive
  - ① Exaggerated FDT for Obliques
  - ② AFGT.

entrop

Tech

- Anaesthetize Eye ≤ 1% paracaine

Supine, Speculum

Look in direction of action of mal. (Relax Antag)

Eye held at limbus ← fixation forceps / Pierse Hoskin's / Special Scott's.

- Lift for secti (At Equator)
- push for obliques (Behind Eq)
  - rotate in direction of mal
    - free → neg
    - Restriction → +ve

Ask pt to look in direction of action of mal

- Fug → Normal mal → Restrictive element +nt → R
- Weak → Paretic → Restriction + Antag → P

(B) — see in Vertical Squint

III N Palsy

- Nuclear
  - Causes
    - Infarcts
    - Dpg
    - ↑ ICSOL.
    - Infective granuloma.
- Infranuclear.
- Fascicular
  - Complete → Intracranial
  - ½
    - Sup Trunk
    - Inf T
    - → IntraOrbital

Total ½.

Mol involved

- ExtraOcular
  - LPS
  - SR.
    IR.
    MR
    IO
- IntraOcular
  - Ciliary Mol — Accomo
  - Sphincter Pupillae - Mydriasis

Look for Pupil

- Involving
  - 90%. Compressive Lesion ⇓ Sx
- Sparing
  - 32% involve else in Ischaemic condition. DM, HTN, CAD.
- > Missed
  - Horner
  - Tentorial
  - Uncal herniation Syndrome
- Isolated Paralysis ↓ Botulinum. x P x Acc (✓ EOM action)

- Do fundus exam — look for papilloedema, OA.

PAGE

DATE

- Look for Abducent neg.

SR + MR ⇒ Add on Elevation.

IR + LPS ⇒ Lid retraction on downgaze
(Pseudo Von graefe sign)

Tonic Pupil (CM + SP) — Slow, sustained pupil constriction

- Decide Level — Duane's Rule

Nuclear — Bil Ptosis
Bil Mydriasis, Cycloplegia
Central SR paresis / Bil SR. — Contralateral supply
Incomplete involvement of diff subnuclei
] Common Nucleus

↑
Causes (A)

- Look for 4th N involvement.

Separate Nuc (Fascicular level)

SR — Weak Elevation in Abd
» Ptosis
Congenital ptosis = + Poor Bell's phenomenon
Head tilt ±
Hypotropia. ⇒ Pseudoptosis

If Long standing — Elevation defect even in adduction
⇒ DEP.

Other D.D — Blow Out #
Dysthyroid Orbitomyopathy

Mx 2 issues — Multiple mal
Abducent neg.

Aim — diplopia free 1° & downgaze.

- MR has tone — superomaximal recession 12-18 mm of LR
+
8-9mm resection of MR

⇓

Transposition of Vertical Recti — If VR has normal tone.

⇓

SOA — 12mm. shortened

⇓

Periosteal flaps

MR — Exo in 1°
Adduction Weakness



Paretic
Abd Nystagm. Try adduction

MR palsy. — Convergence ×
INO — ✓

D.D — DHD

Causes — Orbital Restrictive Conditions
Slipped MR muscle after pterygium Sx
DRS type II

IO



≤ SOOA
Incyclotropia +nt
Head tilt to opp side +ve

≈ Brown → xSOOA
Tight SO.

IR » Acquired — Cataract Sx — Bupivacaine myotoxic.
Orbital Tumour

Periosteal anchoring — ≤ Ethibond suture to Medial Wall
Skin — Retrocaruncular approach

⇓

Periosteal anchoring of LR to lat periosteum
+ MR resection 8-9 mm.

- Use of Bupivacaine injection

Double elevator Palsy (DEP)
Monocular Elevation Deficit (MED)

*

Congenital
a) Supranuclear Monocular Vertical gaze palsies
b) Spill over SR → 2° IR.

✓ ✓ 1°

Acquired
Supranuclear paresis of Monocular elevation.

Unil lesion of pretectum.
× Ptosis
× Hypotropia] 1° & downgaze

✓ ✓ → Upgaze

Bell's — N
Doll's Eye — N.

Causes
- Trauma (Blow out)
- Post RD
- Post strabismus Sx

*

a) b) (a+b)

++	IR restriction	elevator paresis
+	FDT for elevation	-
(N)	SR saccades	↓

FDT +ve

FDT
↓
If IR tight/significant Hypo in 1°
↓
Recession of Ipsi IR

free
↓
Hypo in Upgaze
↓
Contralateral SR & IR is weakened.
⇓
Knapp's procedure.
Transp of both MR & LR of Ipsi Eye close to SR.

PAGE
DATE

6N Palsy

Q.

Most common cause – Head inj
↑ IOT. (Localizing sign)
DM

C/F – Esotropia.
Abd limitation.
face turn to same side

D.D

DRS I
Infantile Eso
Mobius syndrome : —— 6, 7N ± B-stem CN
Facial diplegia
Macroglossia

Non Sx like general Paralytic squint.

Sx

a) Weaken Antag → » than usual amt. α ≤ habitually fixate.
8-9mm of MR recession + 10mm LR resection

b) Restrain Contral Antag – Retroequatorial myopexy.

c) Contracture of Antag ✓ → arm FDT neg
⇓
If still persists
Transposition of available mol to aid action of Paralytic Mol
⇓
Hummelshiem's procedure
Temporal ½ of VR
⇓
Jensen's procedure
to LR.

Supranuclear Gaze Palsy as binocular ∴ no deviations & no diplopia.

- Horizontal
  - ↓ Pontine gaze Centres
  - ↓ PPRF
- Vertical
  - Pretectum in MRF. (Mesencephalic Reticular form)
  - ↓ Parinaud Syndrome.

6N palsy

↓ Wait 6 mth for recovery

- Full
- 1/2
  - ↓ FDT / AFGT
    - Good
      - ↓ LR resection ± Botox to Ipsi MR
      - LR fxn
    - Moderate
      - <40
        - ↓ Unil MR ReC
        - LR ReS
      - Eso
      - >40 in 1°
        - ↓ Contralateral MR ReC
    - Poor
      - ↓ Transpose procedure
      - ↓ Hummelsheim Jensen
      - SRT ⊆ MR ReC

Named Syndromes

Gradenigo → facial pain
Ipsi 6N palsy
Conductive deafness
Otitis Media

Godtfredsen → Ophthalmoplegia
+
12N palsy (Nasopharangeal Ca)

Foville → 6, 7 N Weakness
Horner Syndrome
Facial Analgesia
Deafness

Millard Gubler → 6 + 7 Conte Hemiplegia

Hebes → 3 " "

Claude 3 " Tremors

Benedict 3 Hemi + Tremors

Nathnagel 3 + Cerebellar Ataxia.

Raymond 6N + C. Hemiplegia

Kernohan Notch Pupillary dilatation + Contra paresis

Fischer Syndrome — Bil Oculomotor palsy + Ataxia + areflexia

Jacod — 3,4,6N, Trigeminal Neuralgia. Amaurosis.

Paralytic S.

Congenital		Acquired.
At birth/intrauterine	Onset	Sudden
Only in paretic gaze position	Diplopia	+
+	Abn Head posture	+/-
Old photos show.		
-	Past pointing	+
-	Image tilt	Diagnostic.
+	FDT	-
Spread of C.	Comitance	InC.
+/-	2° Msl changes	+
Frequent.	Amblyopia.	X
field of same size	Hess Chart	Smaller
✓	Facial Asymmetry	-
✓	Contracture of Antagonist	-
+	FDT	-

Rx of 3N palsy

of Pseudo / Inverse Duane rxt

Adduction → elevation of lid
Ptosis getting corrected.

So if RE affected — do LR supramaximal recession in LE
- as faden's

↓

weakens LR / Contralateral msl

↓

Eyes goes into Eso

(fixation Duress)

↓

So to correct Eyes (RE) try to adduct to maintain 1° position

↓

MR adduct

↓

elevation happening

fixation duress → Rx of Nystagmus
LR palsy
faden on Contralateral MR
Adv in. 3N palsy.

PAGE
DATE

INO

due to MLF / MS
\ Ischaemic infarction

Ipsilateral adduction def ⊆ Contralateral Abduction Nystagmus
⊆ intact Convergence.

CPEO

Chronic Progressive External Ophthalmoplegia

Ocular Myopathy

⇓

Unknown etiology.

No neurologic involvement

CPEO + | Kearns Sayre Syndrome

Ocular Myopathy + Tapetoretinal deg + Various degrees of heart block

- Bil, Symmetrical, progressive Ptosis.

Cosmetic Squint Sx ⊆ Crutch glasses.

Restrictive Strabismus

Congenital (Innervational)

- Duane's Retraction Syndrome
- Brown's SO Sheath Syn.
- Congenital Dual fibrosis
- Strabismus fixus

Acquired (Mechanical)

- Dysthyroid Orbitomyopathy
- Pseudotumour
- Myopic myositis
- Parasitic Cysts.
- Orbital Tx
- fibrosis 2° to trauma & Sx.

Duane's Retraction Syndrome.

Stilling. Turk & Duane's
Musculofacial innervational Anomaly

Features
- Limitation of Abd or add
- Narrowing of palpebral aperture
- Retraction of globe on abd ± shoot ↑ Up / ↓ Down.

Pathology – Abn & paradoxical innervational impulses to horizontal recti on abd & add

Abd	Add	Co-Contraction
↓		globe
LR, MR relax	LR, MR acts.	↑ I° ↓
↓	↓	↑ ↓
Protrusion of globe.	× Add	Up Retracts Downshoot
Widening of PF	Retraction.	like signs of Horse.
	Narrowing of PF	

Types

I	Ab	LR innervation	–	Ab ×
	Ad		+	Ad limited ⊆ sets
II	Ab.		+	Ab – N
	Ad.		+	Ad limited ⊆ sets
III	Ab	LR+MR	+	limited Abd ⊆ retraction
	Ad			" Add " "

Eso

Exo

clinical

Eso DRs | Exo DRs. | Other DRs.

Cranial Congenital Sysinnervation Disorder →
MRI showing abn in innervation.
Mal hypoplasia.

Variants

- DRS sine Retraction → ↓ ×R.
- LPS → ↓ Widening of PF
- IO → ↓ V aperture ⊆ hyper. in 1°
- SO → A. ⊆ hypo
- Vertical sect. hypo or hyper in 1°

Associations Embryogenic defect 7 WK.

a) Goldenhar's Syndrome OAV.
b) Klippel feil Anomaly
c) Wildervanck Syndr → KF + Deafness

Other Anomalies — Systemic Anomalies

Dx
- Paradoxic deviation
- LE.
- Bil
- Sex.

DoD

LR palsy — Retr globe in Abd.
III N. — Add × Abd limitation.

- MR entrapment in # Medial Orbital Wall ⇒ Pseudo Duane.

Syndrome = Retr in Abd.

Mx →

If. BSV ≤ acceptable Head posture

↓

No Sx

) LR motility prognosis is poor ∴ explain to the patient.

Sx

Mild DRS	Mod-Severe	V	A
↑	↑	↓	↓
Eso	Exo	Hyper	→
⇓	⇓	↑	↑
MR recess.	Ipsi recession of Both LR & MR	IO recession	SO weak.

× RESECT in same eye. Do in contralateral

- MR resection + Periosteal fixation of LR.
- Recession + Retro Equatorial Myopexy
- Y splitting
-

Brown's Syndrome

SO Sheath Syndrome.

cephalization funda.

Congenitally tight SO

features

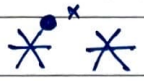

- No elevation in adduction
- No elevation in 1° & Abd.
- × or ↓ SOOA = If ✓ ⇒ Brown + (Plus)
- + FDT
- + Exaggerated FDT
- Frequent depression of Eye in adduction
- Y in upgaze.

Etio

- Trauma
- Infection of Trochlear area
- 10 incarceration foll blow out #
- SO tucking Sx
- Canine tooth Syndrome. – SO palsy + Acquired Brown's



Types Eustis, O'Reilly, Crawford.

	Mild	Moderate	Severe
Elevation in Add	R	R	R
Downshoot 1°	×	✓	✓
Hypo	×	×	✓

Mx Brown has unsatisfactory results
- Complete dissection of SO
- Tenotomy of SO
- Simultaneous IO weak,
- SO lengthening by silicon Expander ⇒ Brown +
- Tried clicked suture in nasal of tendon.
  Loop at insertion site

DoD

Brown		IO palsy
✓	V pattern on upgaze	X
X	SO OA	✓

- Canine tooth syndrome — No ↑ or ↓ in adduction.

PAGE
DATE

Strabismus fixus

- Sf Convergens → Eyes fixed in Extreme add
- Sf Divergens → Exo.

- FDT +ve

Cong.

Acquired
- Myopic Myositis
- Amyloidosis

- Supramaximal Recession of MR ≤ Si Expanders
- Loop Myopexy of LR & SR ≤ Non abs Suture
  Si sling to sclera in Sr Quad
- Nasal slippage of SR & Inf slippage of LR.

Congenital fibrosis of ExtraOcular Muscles (CFEOM)

Congenital generalized fibrosis syndrome

Characteristic

- fibrosis of EOM, Tenon's
- Inelasticity of conj
- Ptosis ± chin elevation
- ↑ elevation ± downward fixation of eyes
- Reverted. Convergence on attempted upgaze & divergence on downgaze.
- family H/O.

Associations

Ocular	Systemic
MGJ Winking	VSD
Choroidal Coloboma	Talipes equino Valgus.
Pendular Nystagmus	Uni / facial palsy.
ON hypoplasia.	

Mx

Rule out acquired causes.
Supramaximal recession of Inf. recti (6-8mm) ± frontalis sling
Crutch glasses.

Vertical Strabismus

Hyper / Hypotropia
cyclovertical / not

Pseudo Vertical Squint — Orbital asymmetry
Displaced globe by an Orbital Mass
facio-Maxillary fractures
Vertical ∠ kappa.
Displaced Macula.
Ptosis.

Types

- Comitant
- Incomitant
- DVD.
- Cyclovertical motility abn ≤ horizontal deviation

Incomitant:
- Neurogenic palsy
  - Supranuclear
  - Nuclear
  - Infranuclear
- Myogenic Dysteophy
- Restrictive Squints.
  - Vertical DRS
  - Brown's
  - CMF
  - Dysthyroid
  - Post Trauma
  - Tx, Pseudo Tx
- Deviations ≤ 1° OOA.

cf

- Vertical diplopia. — gaze in which diplopia ↑
- V. deviation. (B)
- Head posture — Type
  Duration
  Old photographs
  On correcting Head posture — BSV
  diplopia | manifest

(B)

Subj

Diplopia charting
Hess.
Maddox.
Double Maddox
Binocular fields of fixation.

Obj

Hirschberg's test
Cover | Uncover
PBCT!

- Limitation of Movement
- Head tilt test — Park 3 step test.
- Diplopia charting
- Double Maddox. Rod
- FDT
- Exaggerated FDT.

PAGE
DATE

FDT — Reverse Leash effect — If restriction is on same side ⇒ +ve FDT. ⇒ due to Retrosequational fixation.

Exaggerated for Obliques

retract, abduct

SO → Extort

IO → Intort

everything opp to mol action

⇓

Mol is taut.

Abd → Add againts

Upper lid margin. → SO

Lower Lid margin → IO.

If light gives Click

Dissociated Vertical Deviation

Spont upward turning of dissociated eye
On recovery slow drifting reversal movement is Dx
Reason for diss → fatigue, dreaming, covering of 1 eye ≤ occludes.

Several names
- Alt sursumduct"
- " Hypertropia
- Anatropia
- Double hypertropia
- Occlusion

Associatous

- ~~Vertical deviation.~~ Abd.
  - ↓
  - D Horizontal D.
- Exocycloduction
  - ↓
  - D. Torsional D
- Latent Nystagmus
- D. Esotropia / rare

Prevalence
- 2-5yr age
- ass ≤ infantile Eso
- Bil., Asymm.
- Uni → deep Amblyopes & Sensory heterotropias.

Dx tests –
- Spielmann's translucent Occluder
- Bielschowsky's graded density filter bar
- Red filter test
- Uncover test

Etio – Imbalance in binocular stimulation.

PAGE
DATE

100A		AVD.
Max in adduction Never in Abd.	Hypertropia	Same
Quick refixing	Movement of recovery	Slow drift
underact.	SO	Overact
+	V pattern.	±
+	Pseudoptosis of contralat. SR.	−
−	Incycloduction on Reflexation	+
May be +	Latent Nystagmus	often +
−	Bielschowsky's ph.	+
Alternation ↑nt.	Red filter test-	Red image always lower

Treatment

- Recession of SR.
  - 7-9mm
  - Bil IVD
- Poteroequatorial myopexy (faden) of SR.
  - 1+2.
- Resection of IR.
  - If 1 & 2 not effective
- Total AP of IO.
  - ℞ of choice
  - IO ⇒ depressor
  - ⇓
  - Vomp

Nystagmus

Def Regular, rhythmic, repetitive to and fro movement of the eyes.

Nystagmus	Nystagmoid movements
Regular	×
Rhythmic	×
6/60 or better. Vision	Poorer Vision.

Eg
- Oculopalatal Myoclonus
- Opsoclonus
- Ocular Bobbing
- Heimann-Bielschowsky's Unil Vertical Bobbing

Types or Description.

- Horizontal
- Vertical
  - Upbeat
  - Downbeat
- Rotatory
  - Clockwise
  - Anticlockwise
- Mixed.

Type
- Pendular
- Jerk. — (X)

Amplitude
- Fine: <5°
- Moderate: 5°-15°
- Large: >15°

Rate/freq.
- Slow: 1-2 Hz.
- Medium: 3-4 Hz.
- Fast: >4 Hz >

(X) Based on Alexander's Law

Amplitude Component of Jerk N is largest in gaze of direction of fast

- I°: N in direction of fast
- II°: + slow
- III°: + slow

Binocular

Uniocular.

INO.

Symmetric

Asymmetric

Spasmus Nutans.

direction, Amplitude, Rate

differs

Conjugate.

Dissociated.

Sensory

Motor

High gain instability

Vestibular tone imbalance.

Integrator leak.

Classification.

Physiologic

Pathologic. (#)

End point.

Vestibular

Optokinetic

Voluntary

Sensory (Poor Vision)

Motor Neurological disease

ass ⊆ Strabismus

Nystagmoid condition.

Misc

PAGE

DATE

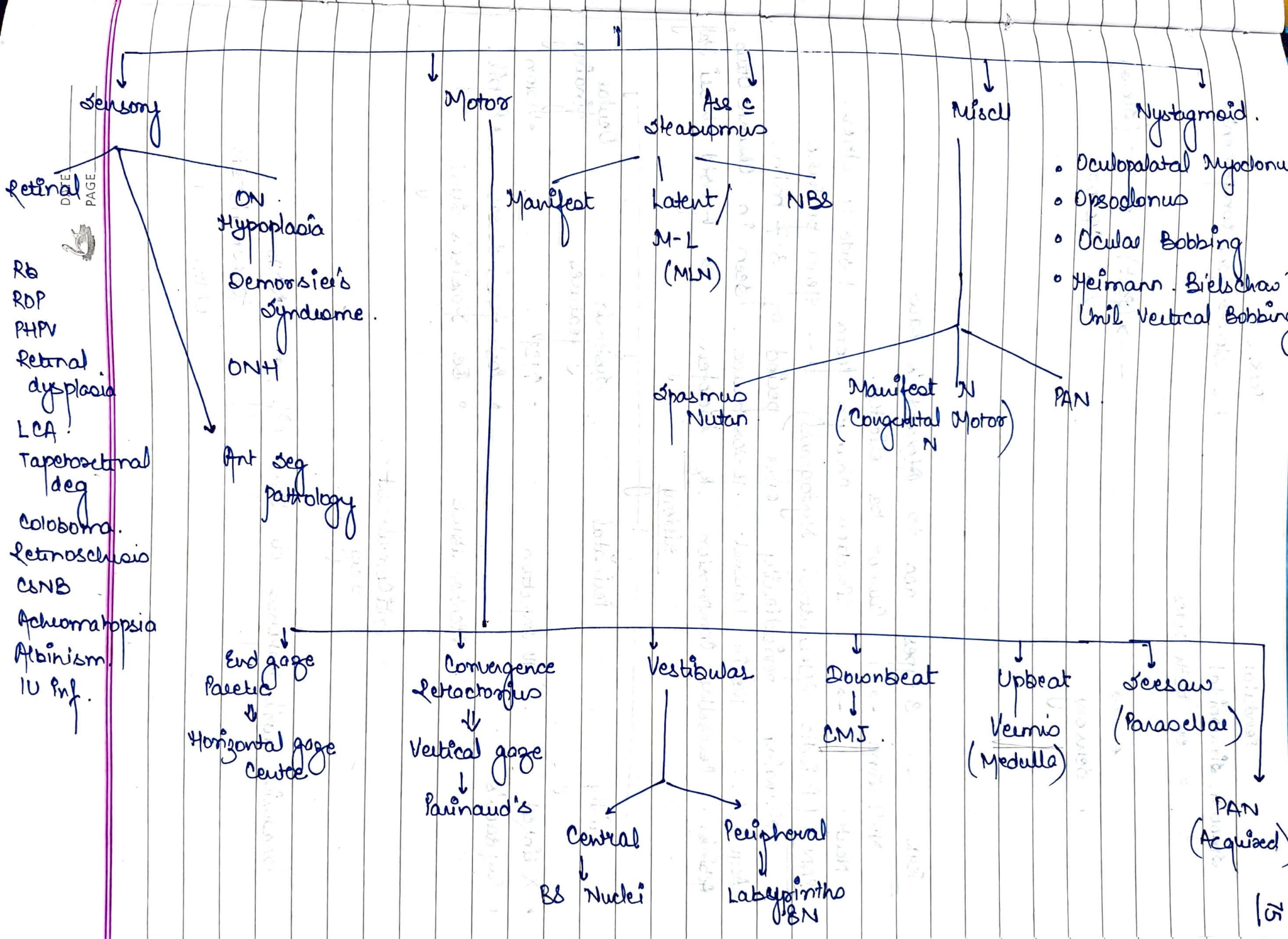

- Sensory
  - Retinal
    - Rb
    - ROP
    - PHPV
    - Retinal dysplasia
    - LCA
    - Tapetoretinal deg
    - Coloboma
    - Retinoschisis
    - CSNB
    - Achromatopsia
    - Albinism
    - IU Inf.
  - ON Hypoplasia
    - Demorsier's Syndrome
    - ONH
  - Ant seg pathology
- Motor
  - End gaze Paretic
    - ⇓ Horizontal gaze Centre
  - Convergence Retractorius
    - ⇓ Vertical gaze
    - ↓ Parinaud's
  - Vestibular
    - Central
      - ↓ BS Nuclei
    - Peripheral
      - ↓ Labyrinths BN
  - Downbeat
    - ↓ CMJ
  - Upbeat
    - Vermis (Medulla)
  - Seesaw (Parasellar)
  - PAN (Acquired)
- Ass c Strabismus
  - Manifest
  - Latent / M-L (MLN)
  - NBS
- Miscl
  - Spasmus Nutan
  - Manifest N (Congenital Motor N)
  - PAN
- Nystagmoid.
  - Oculopalatal Myoclonu
  - Opsoclonus
  - Ocular Bobbing
  - Heimann. Bielschow Unil Vertical Bobbin

Pendular	Jerk.
Smooth, sinusoidal	has slow & fast component
= on both sides	
⟷	→ (fast) ←- - - (slow)
≈ sensory	≈ Motor.

Jerk – 3 types acc to Alexander's Law

Null zone → Cannot be elicited.

Neutral → direction changes from 1 side to other.

PAN (Periodic Alternating Nystagmus) – Head posture changing periodically over period of 3-7 min.

Acquired. 90s in 1 direct – 10-20s pause. Seen in Chronic Otitis, Albinism, Cerebellar Compression. Rx Baclofen. ≈ Arnold Chiari Malf.

History

- Family
  - X linked
  - Tay Sach's
- Perinatal
  - IU infection
  - Alcohol abuse
  - Anti Convulsant drugs
- Systemic features
  - ↑ICT
  - Post fossa disease
  - De Morsier's Synd
- Ocular finding
  - Vision
  - Pupil.

Paradoxic pupil response on light off → CSNB
Achromatopsia.
ONH.

Nystagmus associated with Neurological disorders

(a) Gaze poetic.

End gaze.
» Coarse.
Starts before extreme gazes
Parieto Occipital, Cerebellar, B/L lesions

End point (Physiological)

(b) Vertical gaze

Cong Aqueductal stenosis
Pinealoma.
Hydrocephalus in infants

Retectal | infants
Tectal
Parinaud' Syndrome

(c) Vestibular N. ——— Horizontal Rotatory

Central		Peripheral
×	Vertigo	✓
×	Tinnitus	✓
×	Deafness	✓
Demyelinating dis.	Cause	8th N
Vasc accidents		
Encephalitis		
Tx		
	Oscillopsia.	✓

fixation ↓ ~~on~~ intensity.

(d) PAN

(e) Downbeat

Cervicomedullary Jxn — Rx Baclofen.
Alcohol, Anticonvulsant

(f) Upbeat. — Cerebellar Vermis, Medulla, Post Meningitis

(g) See Saw — Parasellar in 3rd Ventricle. — Hetero Hemi MRI.

Rx — Baclofen.

PAGE
DATE

Electro Nystagmography

- electrodes on both Canthi

Videong → infrared camera.

↑ deflection ↓

Right . Left .

Slow Component — study the velocity

Accelating | Constant | Decelating

Underlying defects

High gain instability → Accelating → MN

Vestibular tone imbalance → Linear velocity → Vestibular N

Integrator Leak → Decelating → MLN

gaze, Paretic / Evoked.

↑ Darkness, Night + Lenses, Closing eyes

↓ fixation .

PAGE

DATE

Nystagmus associated c̲ Squint

- MN 80%
  - else Most common
  - 45% has Squint
  - Variants
    - NBS
    - PAN → Arnold Chiari Syndrome.
- MLN 15%
  - ⇓
  - » Common in Squint Cases (95%)
- NBS
- Spasmus Nutans
- Head Nodding
  - ↓
  - ON glioma/ Chiasma

Manifest Nystagmus – c̲out Cover & x ↑ on covering either eye.

» Infantile

characteristics

- Always bil, Conjugate in direction & freq
- Uniplanar. (» Horizontal)
- Accelating slow phase ✓
- Distinctive Wave forms — J, P.
- Dampened by Convergence, Eye closure. → good. Near Vision
- ↑ on fixation.
- No Oscillopsia
- Null Zone +nt ∴ Head posture
- Head Nodding +nt.
- x by sleep, GA.
- Inversion of OKN.

Latent / Manifest Latent Nystagmus

Elicited on covering 1 eye
↑ on covering dominant eye
decelerating slow phase

- Slow phase → Nasally
- fast phase → Temporally.

- For Documentation of Vision → × Cover.
  - → Use +6.0 to +8.00 lens before other eye.
  - → Use polaroid glasses.

Manifest Nystagmus		Manifest Latent Nystagmus
Biphasic.		Mixed
Mostly Pendular.		Jerky
accelating	slow phase	d accelating
× change	On Covering 1 eye	↑
× change	Direction.	Fast phase ∝ fixing eye
10%	Ass ⊆ infantile Esotropia	✓ 95%
=	Bino vs Mono	>>

MLN ⊆ Infantile Eso.		NBS
		∝ 1
		fixing eye always in. adducti
		∴ 1 eye patch face turn to other
Eye moves out	BO prism	Add continues
Esotropia neutralized		Eso ↑↑.

Congenital PAN	NBS
Spontaneous alteration.	On Alt Covering of fixing eye
∵. Arnold Chiari Malf.	

NBS $\propto \frac{1}{\text{Esotropia}}$.

Add × Nystagmus
Abd ↑↑

face turn ∝ fixing eye ∝ preferred in Adduction.

D.D NBS vs Infantile Eso ⊆ MLN.

Congenital Periodic Alternating Nystagmus
Arnold Chiari Malf.

Treatment of Nystagmus

- Neurological
- Cause
- Non Neurological
  - ⇓
  - Rx

- Non Surgical
  - Optical devices
    - Glasses
    - Contact Lens.
    - Prisms.
  - Occlusion & pleoptics
  - Botulinum. toxin.
  - Medical Rx
  - Acupuncture
  - Auditory Biofeedback
- Surgical

Surgical

- To shift null position to i°
  - ⇓
  - Modified Kestenbaum Sx
- Induce adduction & Convergence
  - ⇓
  - ~~Bimedi~~ Bi- MR ReC/ faden
- ↓ Amplitude
  - ↓
  - supramaximal ReC or faden on all horizontal recti

Non surgical

a) glasses – Over (-) – stimulate Convergence ↓↓ Nystagmus
tinted glasses – Anoxia, Albinism → ↓↓ Optical blur.

(b) CL – ↑ Refractive error ⇒ good stimulus for fusional control
Soft CL → acts as Sensory stimulus to ↓ A.
a+b → Stabilize retinal image

(c) Prisms

- induce fusional Converg
  ≠ PD BO
- Pre-Op Evaluation
  apex – direction of gaze
  Base towards face then
  Dx only

(d) Acupuncture – applied to SCM → ↓ N.

(e) Ploptics – Both Bangerter's & Cupper's
Occlusion – Conventional >> as N ↓ by Amblyopic Rx

(f) Auditory feedback. – using ENG

(g) Medical Rx – Baclofen, Barbiturates, 5HT ⇒ PAN
Memantamine, Gabapentine

(h) Botulinum Inj – Retrobulbar space

PAGE
DATE

Kestenbaum Sx

Modified

Null point assumes head posture.

Shift NP — 1° position by Sx of hori Recti

Kestenbaum - 5mm R&R.

face turn — (L) NP — (R)

LR — ReC
MR ReS
→

MR — C → Anderson
LR — S → goto.
→

Anderson only ReC.

• Parks 5 → 6 → 7 → 8
MR LR
C S C S
⇓
Von Noorden

• Calhoun & Harley
Parks + 2mm for 45°

PAN → Supramaximal R.
Faden.

Vertical

Chin elevation
↓
>25°
↓
SR ↓ S 4mm ↑
IR ↓ C 4mm ↑

For Lesser
↓
Only Rec

Torsional

↳ Vertical shift of Horiz Recti

Head tilt to R
LR ↑ (R.)
MR ↓

↳ Von Noorden.
Shift Vertical Recti horizontal

(R) Head tilt

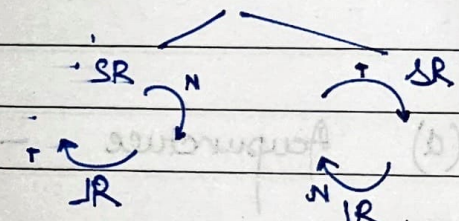

SR N → IR T
SR T → IR N

(X) — Ant seg Ischaemia
↳ Selective advancement & ReC of ant fibres of 4 obliques

(R) HT

R L
10 Advance 10 ✓
50 ReC ✓

← 8mm →

NBS — Post fixation & ReC of MR

PAN — Supra Maximal ReC of all four Horizontal Recti

Other Sx

Retroequatorial Myopexy of all 4 recti

Disinsertion of all 4 recti
⇓
Mestle Dell'. Osso procedure ✓

⟺ efficacy.

Non Surgical Mx of squint

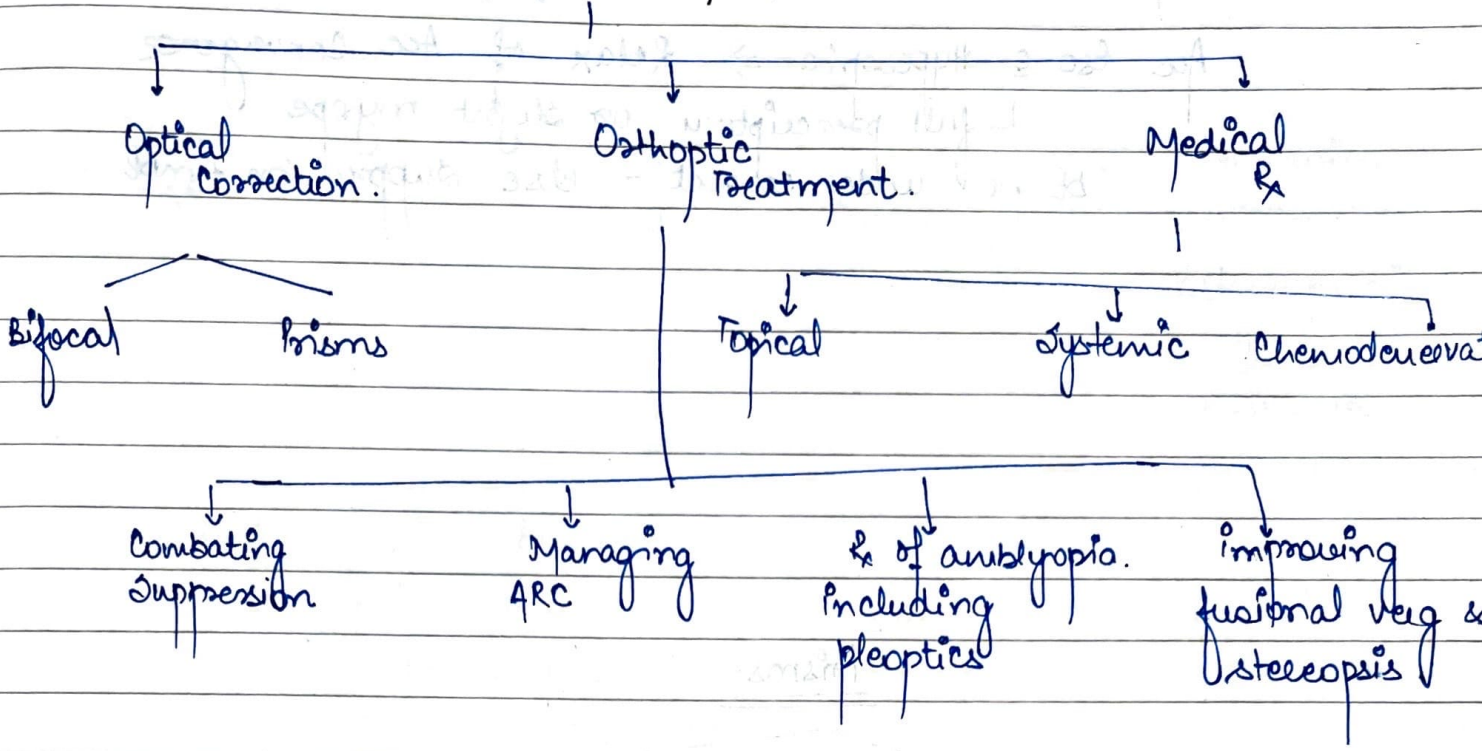

Optical Correction

Use — provide focused retinal image
— proper development of BSV
— Maintain relationship b/t Acc & Convergence.

(a) Proper cycloplegia. — Table

(b) Proper prescription — ∝ Retinoscopy
6mthly — VA check.
yrly — Retinoscopy
Pre-School & Retino not need for PMT

(c) Bifocals — Acc Eso ⊆ ↑ AC/A ⇒ near adds
0.5 – 3.5.
Executive type.

(d) Over Minus glasses — Intermittent EXO ⊆ ↑ AC/A ratio
Inverse bifocal for ~~↑ AC/A~~. Convergence insuff of EXO
(– add for near)

Some pts

Hyperope ⊆ intermittent exo ⇒ fusional control

Acc Eso ⊆ Hyperopia ⇒ Relax of Acc Convergence
└ full prescription or slight myope
bt no under-correct – else suppression Ambl

Prisms

Dx

Rx

Conv insuff

Use ⊆ undercorrection.

for ARC

PAT (Prism adaptation test)

Eso ⊆ ARC has eating up ph.

(x) → Undesirable Optical abberation
↓ Quality of vision
Glasses heavier & Unacceptable.

Orthoptic Rx

- Antisuppression Exs
- Managing ARC
- Rx of Amblyopia including pleoptics
- improving fusional vergs & stereopsis ⇓ » Orthoptic Exs.

(a) **Antisuppression Exs**

- Red filter
- Cheiroscope
- Pigeon / Cantonnet stereoscope
- Physiological diplopia
- Bar reading + zig zag bar, Toval grid.
- Pleoptics & after image transfer tech.

(b) **Managing ARC** Occlusion ↷ Rx ↷ Binocular stimulat

- Prismatic Rx.

(c) **fusional Exs** – NPC, Conv sustenance
SHOT – Pencil push ups

(d) **Amblyopia Rx** Ru. Amblyopia topic.

PAGE
DATE

Medical Treatment

- Miotics & Accomodative Esotropia.
- Cycloplegics
- Other Drugs.
- Botulinum Toxin A

Miotics

MOA Acts on ciliary msl to facilitate accomodation.

↓ acc effort & linked A. Convergence → Miosis → ↑ in depth of focus

Eg

- Short acting
  - Pilocarpine
  - Eserine.
- Long acting
  - Di isopropyl fluorophosphate DFP
  - Phospholine iodide (Ecothiophate)
  - Demecarium Bromide (Humorsol)

Dose Ecothiophate — 0.03% → 0.06% → 0.125%.

↓ Morning & BD.

Indication Children who are too small to wear glasses

Good glasses like Vacatrons

PAGE

DATE

Side effects

Ocular

Bifocal have > predictable result
Brow ache
Iris Cyst
Cataract.
RD

Iris Cysts → 2.5% phenylephrine to Rx

Systemic

Nausea, Vomitting.
Salivation
freq Micturition.
Diarrhoea. Abd. cramps

Also prolong action of GA ⊆ Succinylcholine.

* fore Warn. Anaesthetist.

Cycloplegics

- To make them accept hyperopic correction.
- To suppress AC mech & stimulate divergence.

Other Drugs

- Strychnine
- Chlordiazepoxide.
- Diphenylhydantoin.
- Levadopa.

- To strengthen Mol → Bupivacaine is given in paretic Mol.

⇓

Initial Mol fibre damage ↷ Reg & fibrosis of mol

⇓

Stronger.

Botulinum Toxin. A (Chemodenervation)

Botulus — sausage poisoning ⇒ early paralysis of bulbar & skeletal muscles.

Indications
- VI N palsy to prevent MR's early contracture
- Transposition of VR so given in HR (antagonist) to weaken them.
- Before fibrotic changes in Dysthyroid Orbitomyopathy
- Surgical Under/Over corrections
- Squint after RD
- Retrobulbar inj in Nystagmus
- Blepharospasm
- Hemifacial spasm.
- Infantile Esotropes ⇒ Scott & McNees. ✓

⇓

Before 6mth — good Binocular vision → xSx.

→ Rx of spastic entropion. ∴ Botox

» permanent action bcos of changes in developmentally immature muscles — orbital singly innervated muscle fibres.

- In Lacrimal gland to decrease secretion of tears in c/o epiphora.
- In persistent epithelial defect — for inducing Ptosis.

MOA 150 KDa molecule

↓

(Carboxy) terminus att to gangliosides of surf memb. = Binding step

↓

Endocytosis by Amino terminus ✓ Neurotropic release of Ach

↓

Light chain → × Ach vesicle release → ✓ MEPP

↓

× EPP.

Intracellular poisoning step

↓

blocks Ach release by substrate modifying

Duration of action – 2-4mth
Peak action – 5-7D.

Preparations

Oculinum (100 U) — Allergan (US) (2.5U)
Dysport — Speywood (UK) (40U)

frozen lyophilized form.

Reconstitute c̲ Normal saline ⇒ Use in 4hrs.

Degraded – Vigorous shaking, rapid injection.
pH or temp changes.
Lethal Dose = 40U/kg

Oculinum – 100 U/vial
+
4ml NS
⇓
25U/1ml
To give 2.5U/muscle give (~ Mc Neer)
0.1ml of solution.

Methods of Inj

Inj under EMG
Jxn of Ant 2/3 ↷ Post 1/3
Crackling sound = Quietens c̲ dose injected
↓LA → ask to look in direction of mol

- Avoid mol sheath perf.
- Avoid globe perf.

Complications

- Ptosis
- Paralysis of adjacent Mol — Vertical diplopia
- Dry Eyes.
- ↓ Lacrimation.
- FB Sensation
- Sub Conj & Peteobulbar Hmeg
- Pupillary dilatation.
- Accom. Paresis
- Accidental Injection Into globe.

Effects reversed by – Dinitrophenol 4 aminopyridine
4 - aminoquinoline.
↓ Temp.

Name.	Features
1. Limbal incision of Von Noorden. 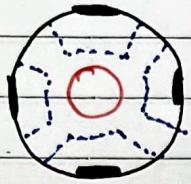	• Segmental peritomy incision ≤ 2 radial incision // to palpebral aperture • At limbus Conj & tenons are fused & can be lifted together
2. Over the mal incision of Swan. 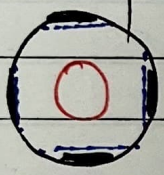	Conj incision is concentric to limbus MR - 1-2mm ant to plica semilunaris LR - Midway b/t limbus & lat fornix. After incision → sclera is exposed sup & inf to mal by cutting through tenon's and intermal septum.
3. Para Limbal incision of Ben Prakash. 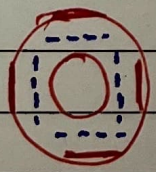	2 Para limbal sutures 2mm & 4mm from limbus are passed. - One retracts Conjunctiva & other retracts the globe - Incision made b/t 2 sutures with spring scissor - Tenon dissected & mal exposed

PAGE

DATE

Conjunctival incisions in squint Sx

Advantages

- Unnoticeable scar
- good exposure of recti
- Makes easy to work in correct tissue plane
- good while doing conj recessions
- & adjustable conj Sx
- good exposure for Vertical recti & IO.

Disadvantages.

Bad scar
Adhesion formation if mkl sheath is ruptured.

Compromise of adv of 2 tech.
Less risk of directing to recti
good exposure

- Leaves a scar.
- Not the incision of choice

PAGE
DATE

Name.	Features
4. Fornix Incision of Parks 	Conj. incision made in sup & inf fornix Made on bulbar conj 8mm from limbus adj to Vertical recti Teron incised ⊥ to incision Base sclera is exposed first
5. Miss (Mojo) Minimal incision Strabismus Surgery 	Two small incisions at upper & lower pole of insertions of horizontal recti - Mat sutured under conjunctiva

PAGE

DATE

Adv.

Hidden scar
Better accepted by pt.
Less irritative.
Less Hyperaemia.

Disadv

difficult for beginners.

Only for small recessions & plications in place of resection.

Weakening procedure in Recti Msl.

- Recession
  - Conventional
  - Hangback or Hemi hangback
  - Adjustable
  - Slanting recession
  - Vertical transposition of horizontal recti
- Retroequatorial Myopexy (faden)
- Marginal myomectomy
- Myectomy
- Free tenotomy or dis insertion

Recession

- Procedure where msl is disinserted & re-inserted to a point closest to its origin.
- Induces a slack or laxity in muscle as its length tension relationship changes.

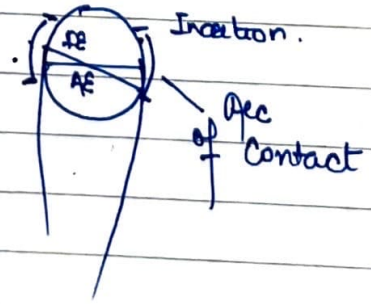

Recession

- c in.
- arc of Contact
- beyond

+ Msl action −

So maximal limit is fxn. equator.

	LR	MR
ff.	2mm post.	2mm anterior
Maximal limits		
L Adults	8mm.	6mm.
L Children.	7mm	5mm.
Minimal limits	4mm.	3mm.

Advantages of recession -

More predictable
Can be undone
Can be resisted to augment the effect
Effectivity has made disinsertion obsolete.

Types of recession

a) **Conventional** – fe inserting the rectus muscle with two sutures directly to scleral points where insertion is intended.

Hang back recession

- full
  - long ends of suture s/t site of insertion & the muscle
- Hemi
  - sutures passed through a scleral tunnel before being inserted at level of original insertion

PAGE
DATE

4) Hang back — Hemi

Indications

Supramaximal recession is intended & its difficult to pass sutures that posteriorly

If disinsertion or tenotomy is being considered

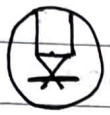

Adv

In Myopes where chances of scleral perforation is high

Advantage of recession in muscle which is not totally free to attatch anywhere

Width of mal broader than hangback.

Less chances of post op creeping forward due to long hangback.

Disadv

Weakening more than recession

Pseudotendon formation in the intervening space leading to late under correction

If suture give way ⟷ as bad as disinsertion

PAGE

DATE

c) Adjustable recession

Ability to modify position of newly operated muscle by use of adjustable sutures

- After → effect of anaesthesia
- Before → healing commences

Technique - classical method by Jampolsky — recessed muscle is sutured to globe in such a manner that sutures are loosened & adjusted forward or backward acc.

Adjustment tech

a) Partial distance scleral tunnel — limits forward pulling

b) Peter Jell's tech - suture is passed at insertion ⇓ Proper width of mal recessed.

c) Sliding Noose suture — Crumpled mal.

Readjustment

- Within 24hrs
- After a week — for more predictable results — but not easy

~~d) Vertical transposition of horizontal recti~~

Ix

- Large angle deviations where results are inconsistent
- Due to altered mal facial factors — leading to unpredictable surgical planning - re-operations
- Inaccurate assessment of mal fxn due to previously injured EOM
- Incomitant strabismus with diplopia - requiring precise post op results
- Severe Mechanical limitations as in dysthyroid orbitomyopathy
- Absent innervation in 3rd N or DRS.

(d) Vertical transposition of horizontal recti

- done for AV patterns
- Shift the mal in the direction you want to weaken them
- MR shift towards the apex.

Eg



ESO

More ESO in downgaze

⇓

MR to be weakened in downgaze

shift MR down.

(e) Slanting recession

Differential recession.

Slant MR with more recession of

Inf end. — Superior end

↓ — ↓

V Eso — End toward apex — A Eso.

Eso — MR

Exo — LR

A Exo — V Exo

↓ — ↓

Inf End — LR (End towards base) — Sup end.

Retro-equatorial myopexy (faden)

faden — German means suture

Posterior fixation suture or faden ⟹ Cuppers.

Concept Mal sutured post to its insertion farther than limit of arc of contact

⇓

Shortens lever arm

⇓

Reduces action of mal in field of action

» MR Least for LR.



Ix

Non accomodative convergence excess Eso

NBS

DVD

Paralytic strabismus (Contralateral synergist)

DRS (Contralateral MR)

Additional weakening effect over recessed mal for reducing amplitude of Nystagmus

How to we decide if 1 eye or 2 eye R & R to be done

If some residual action ↑nt — R & R (Same eye)

Total loss — Supramaximal LR recession
LR att to periosteum
MR globe fixation to periosteum

Resection MR → >8mm. -10mm) (Normally 6mm)

PAGE

DATE

Marginal myotomy — Transverse cuts are made in mal alt at borders atleast 2/3 width of mal

- Effectively lengthen mal like steaightening the Z.
- Shd be done last

Myectomy — done of 10 else obsolete

Disinsertion or free tenotomies — Rarely done for fibrotic recti where recession not possible or extreme situations of dysthyroid orbitopathy

Obsolete as highly unpredictable difficult to redo or Undo.

PAGE

DATE

Strengthening Procedures on Recti

- Resection
- Advancement
- Double breasting or Tucking
- Cinching
- Transpositioning of adjacent muscles.

Resection — shortens length → make it taut
↓
Improve efficiency by ↑ length tension Curve

R. of tedinous part of mol only
× mol mans else mycchemy ⇒ Weakening
IO has × tendon ∴ Resection.

	Max.	Min.
LR	9 mm	4.5
MR	6 mm.	3

Advancement – Msl inserted closer to limbus
↓
stretch the msl
↓
More taut & effective

Reverse of recession

✓ • Consecutive squint – where recession has been done earlier

× Risk of congestion in paralimbal area

• Paralytic squint – Adv + Resection.

Double breasting / Tenoplication – Msl is shortened without excising the msl mass by double breasting tendinous/msl part.

✓ – Paralytic s where thin fragile msl is present.

» SO done.

Cinching – Modified double breasting where passage of suture
↓
To cause double breasting of msl.

✓ → Msl not disinserted
Ant ciliary vessels not compromised.
× risk of Ant seg ischaemia.

Transposition of mol

When strengthening procedure not possible.

Pre-requisites — Absence of restriction of antagonist

FDT — Tight Antag
↓
recession

* → Not to risk ant segment circulation

Ix
- Paralytic S.
- Slipped or Lost Mol
- SRS.

Use

↳ Knapp's Procedure. MR & LR. Close to SR. Elevator underaction.

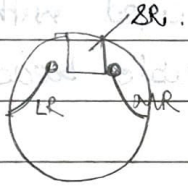

↳ Hummelsheim's procedure
Lat ½ of SR & IR dissected upto 14 mm.
↓
inserted adj to. LR

LR palsy
Lost MR mol

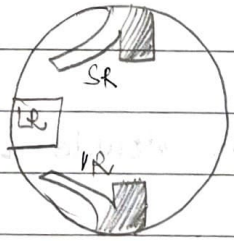

PAGE
DATE

- **Jensen procedure** — LR palsy
  lat ½ of SR, IR and upper, lower ½ of LR
  dissected abt 14 mm from their insertion
  ⇓
  tied with 5-0 Mersilene.
  ⇓⇓
  ↓ Ischaemic chances

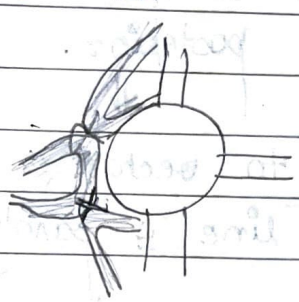

- **Callahan's** — ½ of M & L secti tied with 2 ½ of SR. — elevator palsy

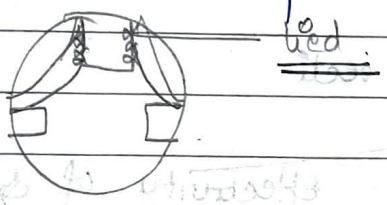

- **Peter's procedure** using SO. — AR in 3rd N palsy
  without removing SO from tendon
  it is shortened by 16-20 mm.

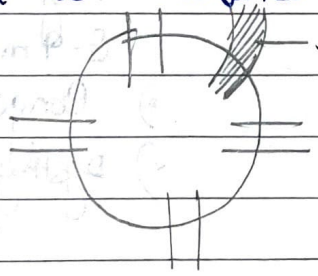

- **O Connor** — LR cinch ⊆
  transposed SR & IR to LR.

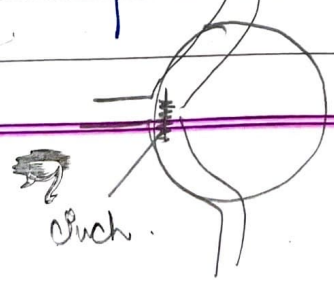

PAGE
DATE

Helveston's procedure

Glycerine preserved sclera 1.5×100 mm used

↓

To transpose ½ of SR & IR to MR.

⇒ Scott's Foster Augmentation

↓

Post fixation suture on transposed ½ 8mm posterior.

⇓

to vectorize forces in line c paralytic msl.

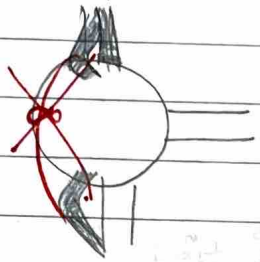

Points to consider in Sx of Vertical recti

- Changes in lid position.
  - >5-6mm Sx should remove. dissect attatchment that causes changes in palpebral aperture.
    - IR
      - C → Ptosis LL
      - S → elevation
    - SR
      - C → UL retraction
      - S → Ptosis of UL
  - Downgaze cutical as check ligaments of VR. att to
    - SR → Whitnall's lig.
    - IR → Lockwood lig.
- Effectivity of Sx
  - Max 5mm
  - Min 2mm
  - Large 8-9 mm
    - Congenital msl fibrosis
    - Dysthyroid Orbitomyopathy

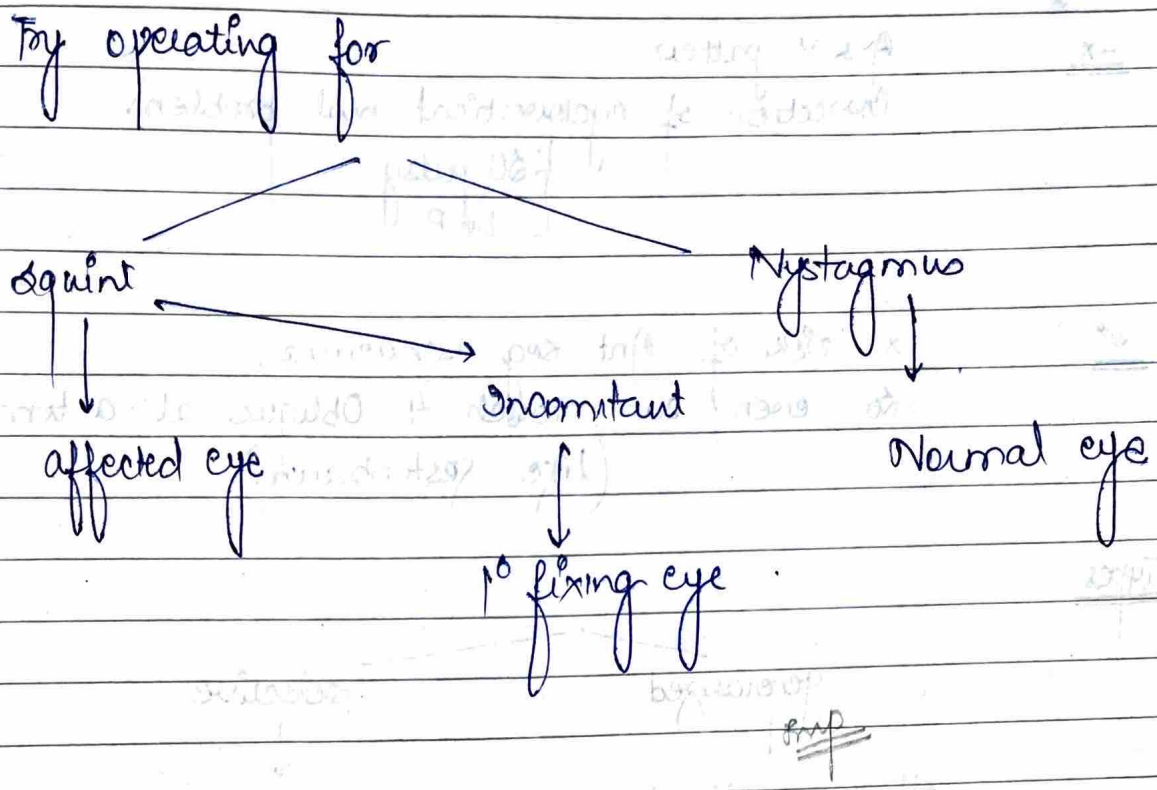
Fx operating for
squint
Nystagmus
Incomitant
affected eye
Normal eye
1° fixing eye

FP

Surgery on Oblique mal

Ix

A & V pattern.
Correction of cyclovertical mal problem
- SO palsy
- DEP.

✓

x risk of Ant seg ischaemia.
So even can touch 4 Oblique at a time
(Like Kestenbaum)

Types

- generalized
  - effect on all fxns
- selective
  - effect on selective fxn.
    - Vertical
    - Abd.

- Ant fibres
  - Torsional
- Post fibres
  - Abd
    - Elev — IO
    - Depr — SO

10

Procedure

Weakening

Generalized
- Recession
- Myectomy
- Disinsertion
- Denervation
- Extirpation.

Selective
- AP & recession
- Pure AP
- Total AP
- Recession of Ant fibers.

Strengthening

Generalized
- Advancement
- Resection / Double Recasting

Selective
- Advancement of ant fibers

30

Weakening

Generalized
- Tenotomy (T/N approach)
- Tenechomy
- Recession
- Translational recession
- L lengthening
- Si expander lengthening – Loop tenotomy at Insertion

Selective
- Post tenotomy
- Post tenechomy
- AP
- Recession of ant fibers.

Strengthening

Generalized
- Tucking (Tenoplication)

Selective
- Tenting of nasal fibers (Harado ITO & its modifications

100

Weakening Procedures on SO.

Ix

- A pattern deviations c̲ SOOA
- Brown +
- Torsional Kestenbaum Sx

Operations from temporal safer than nasal as

SR

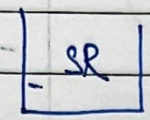

T N — fascia around SO is not having distinct sheath

⇓

∴ dissection c̲ ↓ temperation.

Superior limbal incision.

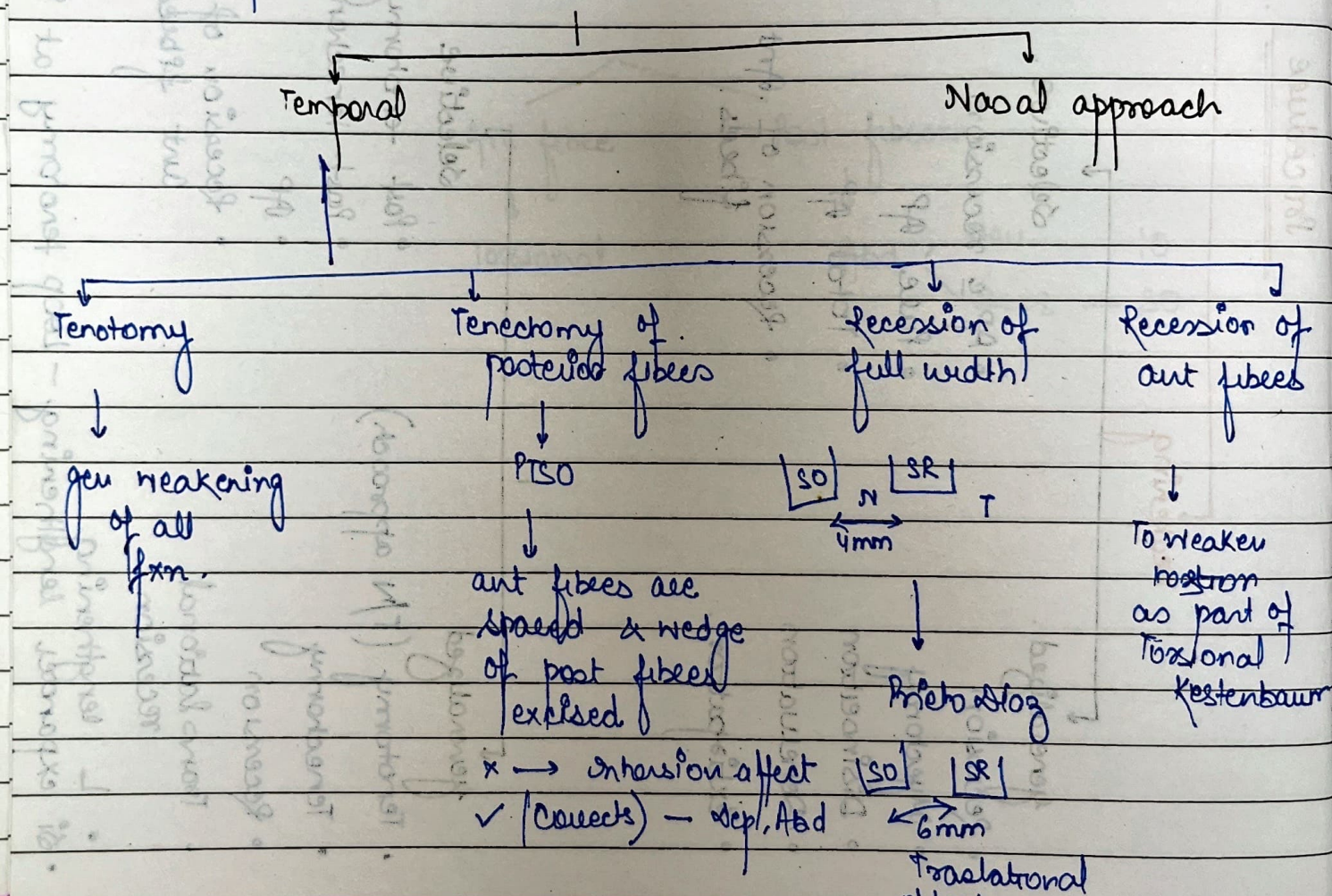

- Temporal
  - Tenotomy
    - ↓ gen weakening of all fxn.
  - Tenectomy of posterior fibres
    - ↓ PTSO
    - ↓ ant fibres are spaced & wedge of post fibres excised
    - × → Intorsion affect
    - ✓ (Corrects) — Dep, Abd
  - Recession of full width
    - SO N SR T
    - 4mm
    - ↓ Prieto Diaz
    - SO SR
    - 6mm
    - Traslational effect
    - 12mm from limbus
    - No limitatⁿ of ↓ in Abd
  - Recession of ant fibres
    - ↓ To weaken rotation as part of Torsional Kestenbaum
- Nasal approach

Nasal approach

- Tenotomy or Tenectomy
  - ↓
  - 30 transection done
- For. silicon band. expander lengthening
  - ↓
  - » temporal app
  - 2. 5-0 prolene sutures passed 1cm apart
  - ↓
  - ✓ Maintain fan shaped incision of 30
  - ↓
  - X → Adhesions
- Split tendon
  - ↓
  - by Cancia.

PAGE

DATE

Steengthening procedures of SO

Tucking or Teroplication
↓
T>N approach
↓
4+4mm double folding for 3+ SO
↓
Suture loop temporally
↓
Do Exag FDT for SO.
↓
x tight.
else induce Brown Syndrome.

Harado - Ito procedure
↓
Selective steengthening of intorsion.
↓
Ant tenting of ant fibres
Nasal
↓

Selective tucking of ant fibres
↓
SO paresis ≤ intorsion defect.
part of Torsional Kestenbaum.

Complications of Strabismus Surg

Intraoperatively

Surgical

a) Operation of Wrong eye
b) Operation on wrong Mol
c) Wrong Operation performed.
d) Haemorrhage
e) Scleral perforation.
f) Splitting of Mol fibres
g) Loose suture & ½ thickness suture in the muscle
h) Central sag
i) Lost mol or slipped mol
j) Mol sheath, tenon's rupture & fat prolapse.

Anaesthesia related

a) Cardiac arrest
b) Bradycardia
c) Malignant Hyperthermia
d) Allergy
e)

- Operation of Wrong Eye → Mark it → Explain pt.
  Horizontal – anyways has to do 2 mol
- Operation on Wrong Mol – due to torsion
- Wrong Operation performed – Recession ↷ Resec
  +1 mm for ReS

PAGE
DATE

g ery

Post Operatively

- Vomiting
- Infections
- Suture granuloma & reactions
- Tenon's prolapse & Conjunctival cysts
- Sclera
- Anterior Segment Ischaemia
- Over Correction & Under Corrections

- Haemorrhages → 2 planes — Conj incisions
  Dual dissection
  Wet field Cautery → Swabs.
  Extracautious for Faden
- Central Sag » Hang back procedure
- Loose ½ suture → Lose Weakening than req.

PAGE
DATE

Scleral perforation → 3 steps – Conj limbal incision.
– Dissection of tight sect. & tenting of thin sclera
– Passing sutures for mal fixation

- Spatulate Needle
- Small ½ Circle Needles
- 0.5mm stump

- Lost mal/slipped mal → confirm by linear pattern of mal fibres
→ give stay suture.

- Bradycardia → Oculcardiac reflex.

- Malignant Hyperthermia. → ↑CPK levels.
Temp Noting & tetanus
I.V Dantrolene.

- Suture granuloma. → ↓ ≤ 6-0 ⇒ hyperaemia + nt
→ Silk.
← Rx by steroids!!

Over & Under Corrections 10% → Under. Corrections
5% → Over

Ant Segment Ischaemia. →

Corneal edema, thinning, Nou pigmented KPs
Segmental iris atrophy & distorted pupil
AC flare
Late ⇒ Cataract, Phthisis.

>2 mal.

» prone → Atherosclerosis & hyperviscosity

℞ — Steroids

Absent MR — Modified Nishida Tech

Algorithm for Transposition

Limited Ocular Rotation

Duction short of midline → FGT

- Weak to No force → Saccadic Velocity Analysis
  - <100 → Transponse
  - >100 → PES
- Moderate → PES

Duction past midline → PES

Mst facial Anomalies

↓

Congenital cranial dysinnervation disorders

1°

2°

3

↓

CFEOM

MGJW

4

↓

Brown

Facial palsy

6

DRS

Goldenhaar

Klepel field

Holt Oram

Mobeius

Cong steab fixus

Orthoptic Appliances

a) How to dissociate
b) Synoptophore.

How to dissociate 2 eyes

- To know which eye is seeing
- Break binocularity ⟶ 2 physical spaces
  - Septum
    - 2 tubes
      - Red green glasses
        - Polaroid dissociation
          - Bagolini steated glasses

Synoptophore ↷ Amblyoscope

Principle – Haploscope

2 physical location

⇓

1 physiological localization.

Inventors Devised by Worth

↓

Modified by Black.

Worth → Black. A.

Instrument Design
(Worth & Black) → 2 tubes hinged
short ⌒ long
120° mirrors.

Distal end of tubes – 12.5 cm Convex lens
∴ x accomodation

∴ Can simulate. Conv ↷ Diverg.

Use – Home Vision

Basic design – Clement Clarke International Ltd.

2051	2052	2053
Most comprehensive with all fxn		Very basic
After Image ✓	✓	
Automatic Flashing ✓	✓	✗
Haidinger's Brushes ✓	✗	

Base → AC-DC transformer, Voltage selector.

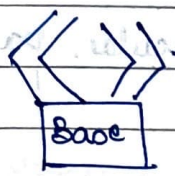

→ Optical tubes → Low Voltage lamps for normal illumination of slides.

At fxn of tube — reflecting mirrors.
Eyepiece — +6.50Ds,
Images at focal pt of eyepiece ∴ × accomodation
↓
If Acc required −3.0Ds lenses (eg for AC:A ratio)

Maneuver optical tubes as we like ⇒
Adjust IPD.

Other attatchments – High Intensity bulbs → After Image creation.
Haidinger Brush.
Slide carriers → Plastic diffusing screen
Iris diaphragm. (To control field of vision)

PAGE
DATE

Variety of slides

Series	A	White	Maddox test
	B		
	S	Blue.	special purpose < AF, AI, Hradinger
	D	yellow.	stereoscopic. vision slides
	F	Green.	fusion slides
	G, H.	Red.	Simultaneous perception
Mayou Series	8.	Orange.	" "

slides for different visual As to test foveal, macular, paramacular perceptions.

Technique

Chin
↓
IPD
↓
slides
↓
Check → deviation — Neutralize perceptions
↓
Lock tubes
↓
fusion ranges
Break pt. Recovery pt

Fxn of Synoptophore

- Diagnostic.
  1) M. of Range of fusion
  2) After image testing
  3) Measurement of deviation.
     - Paralytic squint
     - ARC → obj & subj
     - In different gaze point → Incomitant
     - Hori / Verti] obj. Torsional → Only subj
  4) Assessment of Binocular status
     - Simultaneous perception.
       - foveal
       - Macular.
       - Paramacular
     - fusion.
     - Stereopsis
  5) Adaptability to Fxn. in Aniseikonia.
  6) Cases of Incomplete suppression.
     - Differential Illumination.
     - By using
     - flashing devices
  7) Appreciation of Entoptic phenomenon

PAGE

DATE

Chieuroscope

Principle → It hand reinforces stimulus for the suppressing eye.

Instrument design
- Vertical ~~base~~ picture carried on side
- Working base
- 2 eye piece +8Ds
- Oblique septum cum mirror.

Uses Antisuppression Exs (for superimposing images)

Pigeon Cantonnet Stereoscope

- Anti suppression Exs. with NRC.
- Deviation for near
- Fusion. Vergence determination
- Vergence Exs.
- Stereopsis testing

Uses

3 cardboards

Position 1 – Outer flap flat 180° ~ Remy's seperator Bino ↷ monocular

Position 2 120° – Measurement of deviation.

- Ortho → obj as same gradation
- Heterophoria → difference in gradation
  - Eso → +
  - Exo → -ve.

Reading × 4 = PD.

Stereoscopes

- Holmes
- Keystone
- Asher Law
- Variable Prism
- Cruise.

Reading Bars

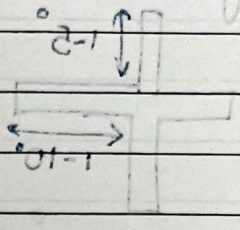

- Reader
- Priesthey Smith's zig zag bars
- Adjustable Mayou Bar
- Mayou.
- Head Band. Bar reader
- Toval grid.

Remy Seperator.

- Wooden, metal septum
- fixed Cardholder.

Stereogram Cards

- Cout Septum

Maddox

English strabismologist — 5m long room.

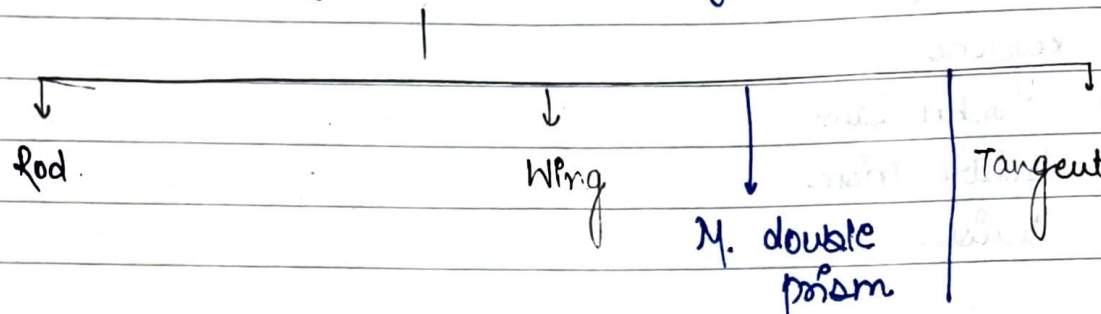

Double M. Rod' test

Tangent scale

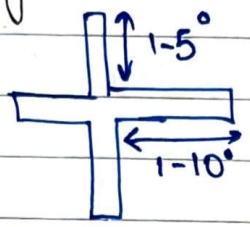

fixation bulb.
Measure deviation & binocularity
Use red glass

Larger figure – 5m. fixation. distance
Smaller 1m.

Maddox Rod

Red coloured disc ⊆ // graves
⊥ to axis of groove

6 cm
33 cm

Rod Cycle.

Horizontal Rod



Horizontal deviation — Vertical deviation

a)



Spot light & scale

⇓

Measure deviation using prism

b) Use Prism bar → line cross fixation light

Pre-requisite — Correction +
NRC
Mature enough child.

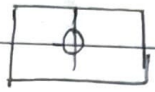
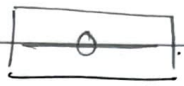
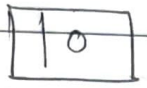
Exo
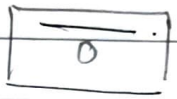
Right hyper
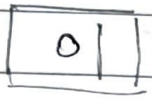
Eso

Right hypophoria

Maddox Wing — Heterophoria for near in PD (34cm)


V — Oblique ⇒ Wing

Metal screen Horizontal & vertical deviation
face piece with 2 apertures

a) Ortho 0 scale
b) Hetero — ↑ white arrow for
c) Cyclophoria → Red arrow // to horizontal scale.

PAGE
DATE

Near Point Rules

- Livingstone Binocular gauge
- RAF Binocular gauge.
- Linear Rule

Break pt. — Recovery pt.

NPC — 6-10 cm.

NPA < 10 cm.



Bishop Harman Diaphragm test

- Detect strength of fusional response
- Screen phoria in pilots

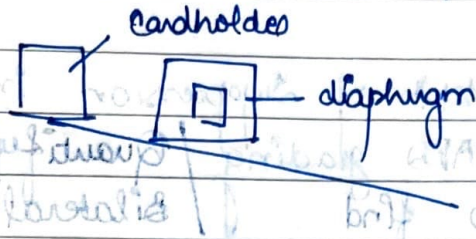

2 groups → Exophoric or Bal response

Crowding or overlap of central no → Esophoric response

2 levels → Hyperphoric

1 side visible → Opp suppression

Ocular Pause Scale reading noted

>4 → Abnormal Binocular fxn.

Prism

Waterm prism
Clip on prism.
Prism mounted in trial lens

Neutral Density filter → depth of suppression in DVD.
→ RAPD grading / Quantifying it
→ To find / Bilateral RAPD

Grade 1 — 0.4
2 — 0.7
3 — 1.1
4 — 2
5 — ∝

Red green glasses used in WFDT.
Hess screen
Lancaster Chart testing
Stereoscopic tests of TNO & Awaya.

↓ Amblyopia in Esotropia & cross fixation.

Maddox Double Prism. → Quali

Cyclodeviation



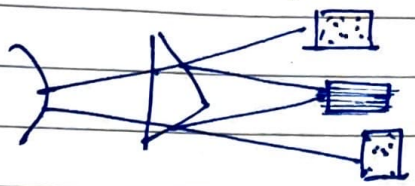



No cyclophoria. Right In. Right Ex.

Double Maddox Rod test → good teral frame. Moddox Rod

Quantify. 6Θ prism. Red. White

cyclodeviation. ⊥.

If deviation

+ −

✓ Prism. × Prism used



Rotate rod →

//.

Amblyopia

- Def
- Types
- features — Neutral Density
  Crowding.
- Rx.
  - Occlusion
  - Drugs
  - Electroptics
- Trials
- Recent Advances.

PAGE

DATE

Examination of case of squint

Complaints

Deviation of eye
Asthenopia

a) Rule out Squint or Pseudosquint

↓

b) Determine Comitant or Incomitant $\begin{cases} 1^{\circ} \\ 2^{\circ} \text{ deviation} \end{cases}$

↓

Measure ∠ Kappa or Do HBT

↓

See type of Tropias

- Cause Wise
  - C
  - R
  - I
- Direction Wise.
  - Eso
  - Exo
  - Hyper.
- Laterality Wise
  - Uni
    - Alternation + or -
  - Bil

•) Head posture

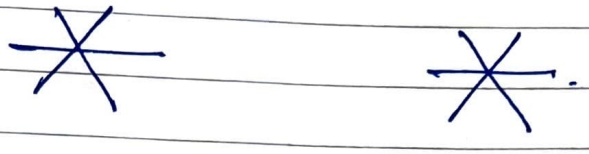

H&T

Cover/Uncover.
Alternate Cover test
Cover Prism Test.

Amblyopia

- Crowding pheromenon
- Missing parts of letters
- Error of Refraction
- Fundus
- Steabismus
- Neutral Density filter.
- Eccentric fixation test.
- Vision in dim light =
- +ve Bruckner's test.

Upper limit of &

Amblyopia → 6yrs

Steabismus → 12yrs

Anisometropia → 8yrs

PAGE

DATE

Newer drugs in Amblyopia

- Bicuculline — GABA recep Blocker
- Ach esterase Inhibitors → Plasticity modulated by Cholinergic transmission
- Dopamine → ↑ Cortical plasticity
- Citicoline — Improves membrane ATPase activity
- Donepezil
- Fluoxetine — SSRI
- Levodopa - Carbidopa.

- Bicuculline

GABA → Parvalbumin → Enwrapped by Perineural nets ← Chondroitinase destroys

Maturation ⇒ closing of Cortical period

- Fluoxetine — acts by altering Cortical expression of various HSP & neurofilament which are important for synaptic fxn.

PAGE

DATE

Rx of Amblyopia —
- Refractive Correction
- Occlusion Rx
- Penalization
- Pharmacological
- Home Vision Rx
- Refractive Sx
- Ploptics
- CAM Stimulator
- Red filter.
- Acupuncture
- Transcranial Magnetic Brain Stimulator

a) – Television game
b) Mobile game
Omega fatty acid.
Smart glasses

a) Anaglyphic TV ping pong Anti Suppression trainer

b) iBIT system
Push Pull
Tetris

PAGE
DATE

Hess chart

Which is abn field

Is field compensed

Which msl is underacting

Which msl is overacting

Less over Hess

↓ Suppression

Pt eyes ⇒ visible

Full dissociatn > easily achieved

Dissociating factors that break phoria into tropia

- Short term Occlusion — Cover/Uncover test
- Prolonged Occlusion — Pad & Bandage
- Shape difference — Maddox Rod test
- Colour difference — WFDT.
- Asthenopia.

Asthenopia

↓

patch eye for 1wk.

- persists
  - ↓ Refractive
  - ↓ find out extent & type of error of Refractⁿ
  - ↓ Estimate NPA
    - WNL
      - Prescribe glasses
    - Low
      - Exclude presbyopia
      - Acc Insuff
      - CI.
- ⊗ Nsl
  - phoria
  - Intermittent tropia.

Binocular Single Vision

BSV — Def
Grades
Advantage

Theories of BS fusion
- Horopter
  - Panum fusional area
  - fixation disparity
- Stereopsis / Stereoacuity
  - Monocular clue of depth perception
- Development at Birth

Synergy hypothesis of Panum
- Local sign hypothesis of Hering
- Eye movement hypothesis of Helmholtz
- Suppression hypothesis of Duane & Verhoeff

Theories of Binocular vision
- T. of Correspondence & disparity
- Alteration theory
- Projection theory
- Motor theory
- Theory of Isomorphism

Disturbances in development of BV
- Diplopia & Confusion
- Suppression
- Amblyopia
- ARC
- BSV tests.

PAGE
DATE

DATE
PAGE

Old classification

DR

- Background
- Proliferative
  - Preproliferative
  - Post proliferative
    - NVD
      - On the disc
      - ≤ in 1mm of disc margin.
    - NVE
      - Anywhere in retina.
      - Away from disc.

DRS classification

- NPDR
  - Early
    - −
    - +
  - Advanced
    - Maculopathy
      - −
      - +
- PDR
  - ≤ out high risk
  - With high risk.

DATE
PAGE

Classification

ETDRS (Airlie House classification)

- NPDR
- PDR.

NPDR

- Mild
  - Very Mild
    - 1yr
    - uaneurysm
  - Mild
    - 6-12mth
    - uaneu
    - Ret Hmrg
    - Exudates
    - Cotton wool
    - × IRMA
    - × Beading
- Moderate
  - ≤ in 6mth
    - PDR – 26%
    - High – 8%
    - → 20/Quad × 1-3Q
    - ✓
    - ✓ 1Q
- Severe
  - S
    - 1 or >
    - 4mth
    - 50%
    - 15%
  - Very severe
    - 2 or >
    - 2-3mth
    - 4+2 → 1
    - 4 — All 4Q severe Hmrg
    - 2 — V. beading
    - 1 — IRMA
    - 45%

PDR

- Mild-moderate
  - ↓ NVD, NVE
- High risk.
  - NVD > 1/3 DA
  - NVD + VH
  - NVE > 1/2 DA + VH
- Advanced Eye Disease

DATE
PAGE

Pathogenesis.

Microangiopathy — small BV affected.

Direct hyperglycaemic effects on retinal cells — likely to play role.

VEGF role.

Risk factors

DATE
PAGE

↳ Duration of diabetes — if before 30yr age
Incidence after 10yr – 50%
30yr – 90%
× c in 5yr
] I

II — DR at presentation
Duration ∝ Proliferative dis — not for Maculopathy.

↳ Poor Control DM — I > II
↑ HBA1C — ↑ PDR risk

↳ Pregnancy — Predicatⁿ factors
- greater Pre preg severity
- Poor Pre preg control of DM
- Control exerted too rapidly
- Pre-eclampsia

↳ HTN — II

↳ Nephropathy —

↳ Other — ↑ lipid
Smoking
Cataract Sx
Obesity
Anaemia

DATE
PAGE

Prevalence

40%

> DM Type I —— 90% incidence after 3yrs

Sight threatening – 10%

PDR – 5-10%

Diabetic Retinopathy

DATE
PAGE

Ophthalmic complication of DM.

- Retinopathy
- Iridopathy
- Unstable refraction.

- Recurrent styes
- Xanthelesmata
- Accelated Senile Cataract
- Neovascular Glaucoma.
- Ocular Motor Nerve palsies
- Reduced Corneal Sensation.

- Papillopathy
- Pupillary light near dissociation.
- Wolfram syndrome (Progressive Optic atrophy
  Multiple neurological & systemic Abn)
- Acute Onset Cataract
- Rhino Orbital Mucormycosis.

Grading

Grade I	2.	3	4
Narrowing	Mild - moderate	moderate - mark.	Retinal arteriales N
Sclerosis	Small arteriales		Focal + Constriction
			3+ papilloedema
Light Reflex	Exaggeration		
AV Crossings	Changes + nt	Prominent	
Edema.		+	
Cotton wool		+	
Flame shaped		+	

DATE
PAGE

Keith Wagner Barker

DATE
PAGE

Stage I — Min arteriolar thinning

II — Localized irregularity in arterial bld col
focal constriction of lumen
generalized narrowing
AV crossing changes

III — »
Superficial Exudates & hmrg.

IV — III + papilloedema.

Wong Mitchell

Mild — Localized arteriolar narrowing
Ext " " Any
AV Kink
Silver wire appearance

Moderate — Retinal hmrg { Sup / Deep.
Exudates { Hard / Soft.
Microaneurysm.
Abv + Any

Advanced — Papilloedema II +

DATE
PAGE

Differential Dx

a) Ischaemic Optic Neuropathy < Arteric / Non Arteritic

b) Drusen of Optic disc – Small ONH.
Angiographically vessels are normal

c) Pseudoneuritis/hypermetropic – Ophthal reflexes
× >2D
× Venous engorgement, × Edema, × Exudates
× Enlarged blind spot. × leak on FFA

d) Papillitis – marked papillitis
↓ of vision, RAPD, × signs of ICSOL.

e) Orbital lesion & disc Edema

Treatment

Decompression — Removal of Tx

Dx options for PseudoTx Cerebri — Lumbar peritoneal shunt
Local decompression by multiple slits or a window in ON sheaths

Prognosis

Vision
- Improve
- Deteriorate → Loss of progressive sclerosis at disc

HTN Retinopathy

Types

	Simple HTN ± Sclerosis	HTN ± Involutionary Sclerosis	Diffuse Hyperplastic Sclerosis	Malignant HTN
	Young pt	Older pt	Young pt	HTN nemo-retinopathy
	General Constriction of arterioles	Arterio-Sclerotic retinopathy	Albuminuric or uremal retinopathy	
	Arterioles – Pale & Acute ∠ branching	Nipping & ⊥ placement of veins ⇓ Gunn's sign.	Narrow & tortous ± Nicking at AV crossings	
Flame Shaped Hmrg	+ (Sup)		Multiple	+
Cotton Wool Spots	+		+	+
Hard Exudates	–	+	+ (Macular star)	+ (✓)
Edema			+	
Vision			impairs	Seriously affected.

DATE
PAGE

↓ Vascularity causes - Infarcts
Ischaemia
Direct pressure induced Axonal damage

Fibrous tissue growth

Signs

Blurring of Margins of OD UL Nasal

↓

Reducing Size of Physiological Cup
Blurring of Temporal Margins & spreading outwards

↓

Veins — Arterioles

Veins:
- Congested.
- Absent pulsation even on applying pressure

Arterioles:
↓
Prominent
Red streaks on Swollen disc
Elevated appearance

↓

Disc elevated into mount

↓

Direct — Ophthal — Indirect-

Direct:
Diff 2-6 D b/t foci of vessels at surf & away

Indirect-
↓
Parallax elevated

- Flame shaped & punctate haemorrhages
↓
Macular star formation

resembling Malignant HTN

DATE
PAGE

↑ Pressure

Axonal damage
↓
Atrophic changes
Pale in Colour

resembles Post papilloedema OA
k/a
2° OA.

↓
Arrows changes
↓
Pigmentary changes on Macula

Bilateral
Factors

Amount of Tx.
↓
Frontal Tx
Middle Ear drs.
Swelling >> on side of Tx

Time of Onset
>> Imp.

Foster Kennedy Syndrome

Papilloedema Unilateral
↓
± OA on other side

2/o Tx of Opposite Olfactory groove
" " Orbital surface of frontal lobe
" " Pituitary body

On Flouroscein Angiography - dilation of surface capillaries
Leakage of dye
Accumulation 5-10 min after IV inj as a vertically oval pool surrounding ONH

DATE
PAGE

Microscopy

electron microscope — Engorgement of axons in laminar portion of ON

↓

filled with mitochondria anteriorly — Swollen
Disrupted

Mesoblastic tissue — Thickened
Subpial edema +nt

Macular Star → Retinal exudates distributed radially along the folds may be present in macular region.

Etiology

↑ ICP due to

- Intracranial tumour
  - Ant fossa
- Intracranial Causes
  - Abscess
  - CVT
  - ~~SAH~~
- Malignant HTN.

Pseudo Tx Cerebri — Benign ↑ intracranial HTN
c/ x ICSOL.

DATE
PAGE

Symptoms

Vision – ✕ affected for long

↓

Blackouts initially

↑ size of Blind Spots.

- Headache » recumbent / Early Morning
- Diplopia
- Nausea / Vomiting

Signs

Blurring of Margins { Upper, Lower } Nasal

Hyperaemic
Elevated disc
Definite parallax b/t summit & retina beneath
Hmrg on disc
Reddish hue – opaque
Macular star & Cotton Wool all over.

↓

OD – Pale due to atrophy

↓

Pigmentary changes over Macula

※ Malignant HTN

※ Post papilloedema OA

Post neuritic atrophy

1° Atrophy

Papillocdema

DATE
PAGE

Def → Edema of OD or ONH due to raised ICP
Purely hydrostatic, non inflammatory process

Pathophysio

Earlier — Compression of Retinal Veins

Now

Blockage of Axoplasmic transport
↓
Stasis in ONH

Swelling of OD — Secondary vascular changes at OD

Pathology

Passive edema. without inflammation
↓
Physiological cup gets filled in
↓
Int limiting Memb. raised
↓
NF degenerate
↓
Shows Cytoid Bodies